: Use Only

1997 Abstract Form
r Scientific Presentations
:RNATIONAL SOCIETY FOR
:TIC RESONANCE IN MEDICINE
:TH SCIENTIFIC MEETING

VANCOUVER TRADE &
CONVENTION CENTRE

ANCOUVER, B.C., CANADA
April 12 - 18, 1997

Oral Presentation but
to present as a poster
leo required (available ONLY
Oral Presentations)
Poster but willing to make
resentation
Only

:ATEGORIES
:ATEGORY NUMBER 206

G
—Animal Models
—White Matter
—Vascular
—Functional
—Other
, Neck, Spine and Other CNS
—Coronary Heart Disease
—Dynamics and Flow
—Other
lar—Non-Neuro
t/Chest
men
ourinary—Pelvis
uloskeletal
entional Applications
mics—Economics

:OSCOPY
an Brain—White Matter &
nerative
an Brain—Stroke & Seizure
an Brain—Tumors and Other
al Brain
iovascular
men and Pelvis
uloskeletal
ors—Animal Models
, Body Fluids, and Other
troscopic Quantitation

DOLOGY
ography
Quantification
sion
sion
tional Neuro—Acquisition and
sis
tional Neuro—Models and Mechanisms
oscopy, Non-proton MRI, and ESR
ients and Hardware
Coils
Pulses
d Imaging
on and Artifacts
r MRI sequences/Reconstruction
titative MRI
ge Processing and Display
rast Mechanisms/MTC
magnetic Contrast Agents
r Contrast Agents
y/Bioeffects/Patient Monitoring
ventional MRI
troscopic Localization and imaging
troscopy--Other

ACT DEADLINE:
no later than November 19, 1996.
ghts to accepted abstracts become the
of the ISMRM. No proprietary
on may be withheld by authors.

O:
MRM
fth Scientific Meeting
18 Milvia Street, Suite 201
rkeley, CA 94704, USA

mailing abstracts from outside the
uld allow six weeks for mailing or
tracts by express.

e the name and complete
dress of the first author.

Wen-Ming Luh
sics Research Inst.
edical College of Wisc
. Watertown Plank Rd.
ukee, WI 53226
USA
e (414) 456-4592
(414) 266-8515
mluh@post.its.mcw.edu

of ISMRM? ☒ Yes ☐ No

High Spatial Resolution Functional Perfusion Imaging of the Human Brain using QUIPSS at 3T

W.-M. Luh, P. A. Bandettini, A. Jesmanowicz, and J. S. Hyde
Biophysics Research Institute, Medical College of Wisconsin, Milwaukee, WI 53226

INTRODUCTION

The high signal-to-noise ratio (SNR) per unit time intrinsic to QUIPSS (QUantitative Imaging of Perfusion using a Single Substraction) (1) allows for high spatial resolution perfusion studies. Our motive to do high spatial resolution perfusion studies is that at 64x64 resolution over a FOV of 24 cm, perfusion in gray matter is underestimated due to the partial volume effect with white matter and CSF. In this study we demonstrate that high spatial resolution (up to 256x256 matrix with 24 cm FOV) single-shot QUIPSS at 3T is feasible using partial k-space echo-planar imaging (EPI) pulse sequences.

METHODS

Imaging was performed on a 3T Bruker Biospec 30/60 scanner. A 30.5 cm i.d. three-axis local head gradient coil (2) and an endcapped quadrature birdcage coil were used. In the QUIPSS pulse sequence, at a time TI_1 after inversion of arterial blood, the imaging slice is saturated, and an image is acquired at a later time TI_2. Single-shot gradient echo blipped echo planar imaging (EPI) pulse sequence was used for readout. TE was 27.2 ms for 64x64 matrix, and 14.9 ms for 128x128 and 256x256 matrices with half k-space technique at a FOV of 24 cm, giving an in-plane resolution of 3.75, 1.9, and 0.94 mm respectively. TR was 2000 ms, TI_1/TI_2 were 500/1100 ms, slice thickness was 10 mm and a 30 mm slice selective inversion was used. A time series of 100 sequential images of one axial slice through the motor cortex was obtained during cyclic (40 sec on, 40 sec off) bilateral finger tapping for 64x64 resolution, and 200 images for 128x128 and 256x256 resolution. Conjugate synthesis was used for the image reconstruction with half k-space trajectory. QUIPSS images were processed by performing pairwise substraction of consecutive images collected at TI_2, creating a time series of perfusion images. Functional perfusion images were generated by substraction of the resting and active state perfusion maps, which in turn were generated by averaging the period of the time courses of rest and activation respectively. Baseline perfusion images were obtained by averaging of the whole time seires.

RESULTS

Figure 1 shows conventional anatomical image and the baseline perfusion maps at 64x64, 128x128, 256x256 resolution respectively. More detailed information can be seen in the higher spatial resolution perfusion images. Functional perfusion images with matrices of 64x64 and 128x128 are shown in Figure 2. Averaging of more time-course images for 256x256 resolution is needed to generate functional perfusion images.

DISCUSSION

High spatial resolution QUIPSS perfusion imaging was implemented on our 3T scanner. With the higher SNR and longer T_1 of blood at higher field strength, as well as higher SNR per unit time of QUIPSS technique, it is feasible to obtain perfusion maps in the human brain at an in-plane resolution up to 0.94 mm within minutes. Functional maps of activation induced perfusion changes are also demonstrated at 128x128 resolution.

REFERENCES

1. Wong, E. C., et al.,*2nd Int. Conf. of Func. Mapping of the Human Brain*, S5, 1996.
2. Wong, E. C., et al., *12th Ann. Mtg. Magn. Reson. Med.*, 1313, 1993.

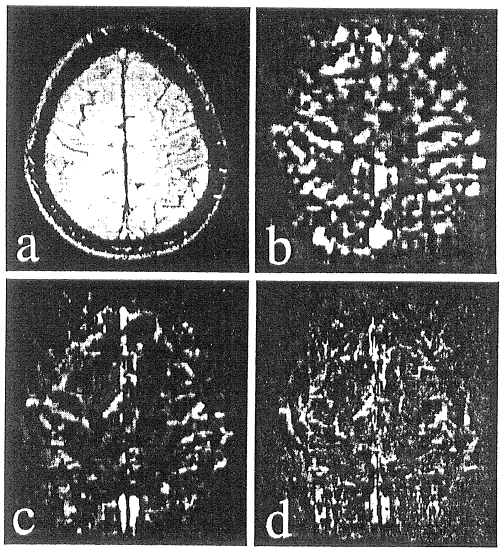

Figure 1. Baseline perfusion images at a) 64x64, b) 128x128, c) 256x256 resolution.



Figure 2. Functional perfusion images of bilateral finger tapping at a) 64x64, b) 128x128 resolution.