Epilepsia, 35(6):1194–1198, 1994
Raven Press, Ltd., New York
© International League Against Epilepsy

Functional Magnetic Resonance Imaging in Partial Epilepsy

George Lee Morris III, *W. M. Mueller, †F. Z. Yetkin, †V. M. Haughton, T. A. Hammeke, S. Swanson, S. M. Rao, ‡A. Jesmanowicz, †L. D. Estkowski, ‡P. A. Bandettini, ‡E. C. Wong, and ‡J. S. Hyde

*Departments of Neurology, *Neurosurgery, †Radiology, and ‡Biophysics Research Medical College of Wisconsin, Milwaukee, Wisconsin, U.S.A.*

Summary: Functional magnetic resonance imaging (FMRI) detects signal changes in brain that accompany regional changes in neuronal activity. In normal human brain, FMRI shows changes in signal in the postcentral gyrus or superior temporal gyrus that correlate with voluntary motor activity or language processing, respectively. The model used to explain the changes in signal linked temporally with cerebral activity is a reduction in cerebral capillary deoxyhemoglobin concentration due to the increased blood flow that accompanies neuronal activity in the cerebrum. FMRI has been used in normal subjects but not extensively in patients. To determine the feasibility of using FMRI to map cerebral functions in patients with partial epilepsy syndromes, we performed a pilot study, using FMRI to identify signal changes in motor and language areas in response to tasks that activate those areas. Signal changes in epilepsy patients approximated those observed in volunteers. We conclude that FMRI can be developed as a method for functional cerebral mapping in partial epilepsies. **Key Words:** Partial epilepsy—Functional magnetic resonance imaging—Functional mapping—Neuronal activity—Deoxyhemoglobin—Regional cerebral blood flow—Epilepsy surgery.

Magnetic resonance imaging (MRI) techniques have been developed to measure cerebral blood flow (CBF) (Shulman et al., 1993). One method detects changes in radio frequency signal in brain linked to changes in neuronal activity. The signal changes are modeled as alterations in deoxyhemoglobin concentration that accompanies fluxations in CBF. Regional CBF (RCBF) increases on the order of 50% secondary to increased activity in cerebral neurons. The physiologic mechanism by which this increase occurs is not fully understood. The increased BF, with only slightly increased O_2 extraction, produces a reduction in deoxyhemoglobin concentrations in capillaries and veins. Decreasing deoxyhemoglobin concentration in cerebral capillaries and veins increases magnetic homogeneity and signal decreases. Therefore, signal intensity in relaxation-weighted MRI acquisitions (T_2- or T_{2*}-weighted) increases as deoxyhemoglobin concentration decreases (Ogawa, 1990). Changes in signal intensity in sequential MRI scans ("activation") have been observed in the precentral gyrus region in association with hand movement (Bandettini et al., 1992; Rao et al., 1993), in the occipital region in association with photic stimulation (Belliveau et al., 1991; Ogawa et al., 1992), and in the temporal lobe in association with auditory stimulation (Rao et al., 1992). The activation is in the range of 2–6% of 1.5 T, and successful imaging of the changes requires high signal-to-noise ratios in the acquisitions. Echoplanar imaging, higher magnetic fields, and specialized coils have facilitated acquisition of the functional MRI (FMRI) scans.

FMRI offers several advantages over other functional imaging techniques for clinical studies. As a noninvasive imaging procedure, FMRI does not require contrast medium injections, ionizing radiation, or radioactive nucleides. FMRI has increased temporal resolution as compared with position emission tomography (PET) or single photon emission computed tomography (SPECT). FMRI provides maps of cerebral function and high-resolution anatomic images onto which the functional informa-

Received June 1993; revision accepted December 1993.
Address correspondence and reprint requests to Dr. G. L. Morris III at Department of Neurology, Medical College of Wisconsin, 9200 W. Wisconsin Ave., Milwaukee, WI 53226, U.S.A.

tion can be mapped; thus it has potential to identify areas of critical brain function and demonstrate their relation to normal structures and pathologic changes. MRI is more widely available than PET or magnetoencephalography. FMRI might benefit partial epilepsy patients being evaluated for surgical management by identifying cortical brain functions near potential resection sites in a noninvasive way complementing or replacing invasive methodologies.

FMRI techniques were studied in healthy volunteers, but not extensively in clinical populations. The effect of cerebral pathology and medications on the sensitivity of the technique in patients has not been evaluated. We therefore performed a pilot study of FMRI in patients with partial epilepsy to compare their responses with those of normal subjects. We selected partial epilepsy for identification of cortical brain function because of known localized metabolism and BF changes that could alter the responses. (Berkovic et al., 1991; Engel et al., 1991).

METHODS

Subjects

Case 1

Three unselected patients with chronic epilepsy underwent FMRI scans. A 32-year-old right-handed woman had febrile convulsions at age 6 months. Complex partial seizures (CPS) had onset at age 25 years and occurred 10 times a month at the time of study. She had been treated with multiple seizure medications and is currently receiving carbamazepine (CBZ). Her interictal EEG showed bilateral anteriotemporal epileptiform discharges, and intracranial subdural recordings showed a clear left anteriotemporal seizure onset. A Wada test lateralized language to the left hemisphere. Left temporal lobectomy was performed. The patient had no seizures subsequent to the operation. FMRI was performed preoperatively.

Case 2

A 31-year-old right-handed woman had seizure onset in childhood. CPS had occurred six times in 20 years, but because of religious preferences no medical treatment had been sought. The most recent seizure occurred 1 month before testing. She had not been treated with medications. EEG showed left posterotemporal epileptiform discharges. Medications were started after FMRI was performed at the patient's request.

Case 3

A 39-year-old right-handed woman had seizures onset at age 4 years after a febrile coma with left hemiplegia. CPS occurred several times monthly. Interictal EEG showed right sphenoidal epileptiform discharges and ictal EEG showed right sphenoidal discharges. A Wada procedure lateralized language to the left hemisphere. FMRI was performed before right temporal lobectomy. Seizures have not occurred postoperatively.

FMRI protocol

Images were acquired on a commercial 1.5-T system (General Electric Medical Systems, Waukesha, WI, U.S.A.) with a prototype 30.5-cm ID three-axis local gradient coil and an elliptical end-capped quadrature radio frequency coil (Wong et al., 1992*a*,*b*). After informed consent was obtained, the patient was given ear plugs and positioned in the scanner. Multiple slices were obtained with a gradient echo technique in sagittal and axial planes (parameters TR 400, TE 10, FOV 24 cm thick:15 mm, 256 × 128/1 NEX). From the gradient echo images, parasagittal slice locations 15 mm thick were chosen to include the lateral border of both temporal cortices. With a multiplanar blipped echoplanar acquisition (Wong et al., 1992*a*) a series of 64 images was obtained in each plane at a rate of 30 images per minute. Each image was acquired in 40 ms with 64 × 64 image matrix, 24 cm FOV, TR 2 s, TE 50 ms. During the 130-s acquisition, the patient alternately rested quietly for 25 s and performed one of the five functional tasks for 25 s. The functional tasks consisted of the following: (a) sequential finger movement—patients tapped each finger of the right hand sequentially to the thumb as quickly as possible; (b) tongue movement—the patient moved the tongue side to side as rapidly as possible, with mouth closed; (c) lip movement—the patient forcefully and repeatedly contracted the orbicularis oris as quickly as possible to produce puckering of the lips; and (d) word generation—the patient recited out loud as many words as possible, beginning with a specific letter supplied by the examiner.

Image analysis

We screened the series of images for patient movement by viewing the images consecutively in a

TABLE 1. *Signal changes in response to specific tasks*

Task	Case 1	Case 2	Case 3	Active region
Finger movement	+	+	+	Bilateral pre- and postcentral gyrus
Lip movement	+	+	−	Inferior precentral gyrus
Tongue movement	+	+	−	Inferior precentral gyrus
Word generation	+	−	+	Temporoparietal region and inferofrontal region

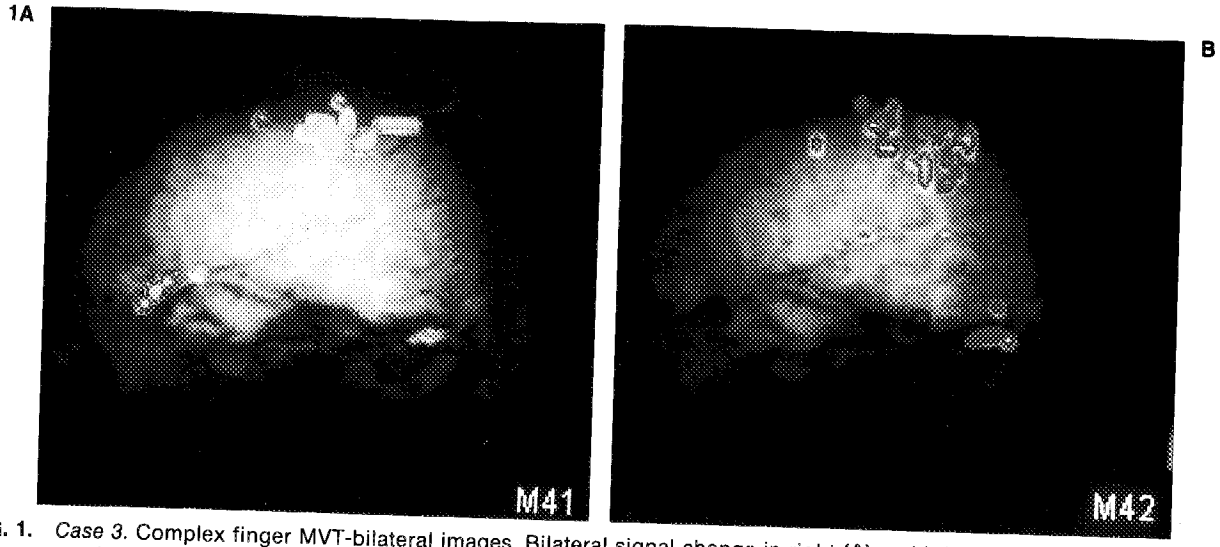

FIG. 1. *Case 3.* Complex finger MVT-bilateral images. Bilateral signal change in right **(A)** and left **(B)** hemispheres associated with sequential tapping of right fingers to thumb.

cine mode (Bandettini et al., 1993). Further analysis was not performed if images were degraded by movement. Signal intensity was plotted versus time for each pixel in each image. Functional images were prepared with an n-dimensional vector analysis program that compares the time-course plot in each pixel to a reference time-course plot. The reference function for this study was the time-course plot with the largest magnitude of changes occurring contemporaneously with performance of the task. A correlation coefficient is calculated between the time-course plot for each pixel and the reference function. Pixels with a correlation coefficient that yield $p < 0.001$ are displayed as positive evidence of task-activated functional signal. The anatomic location of pixels positive for signal increases was determined by superimposing the functional image on the echoplanar image and noting the spatial relation of superior temporal gyrus and central rolandic fissure to the activated region.

RESULTS

Signal changes ≤6% were noted in each patient in response to the specific tasks (Table 1). Signal intensity changes on each task were similar in magnitude in dominant and nondominant hemispheres, in the hemisphere of seizure onset, and the contralateral hemisphere (in 2 individuals in whom the hemisphere was determined by operative outcome) and in patients treated with antiepileptic drugs (AEDs) and the unmedicated patient. Signal intensity changes were of similar magnitude with each of the tasks. Sequential finger movement produced significant signal intensity changes of 3–6% in all 3 patients. Lip and tongue movement and word gen-

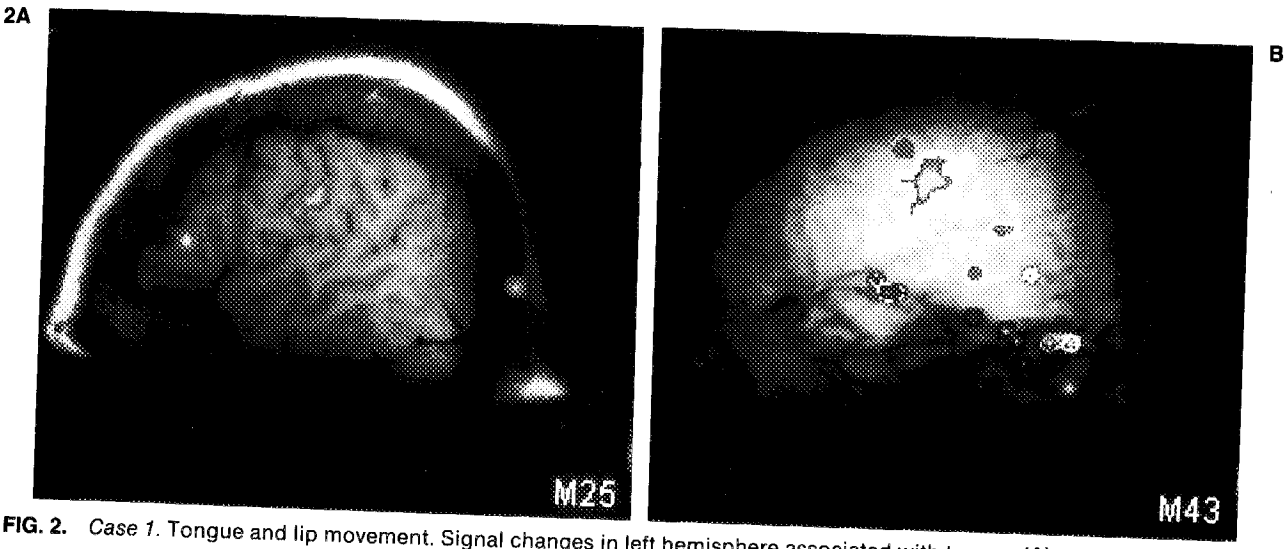

FIG. 2. *Case 1.* Tongue and lip movement. Signal changes in left hemisphere associated with tongue **(A)** and lip **(B)** movement.

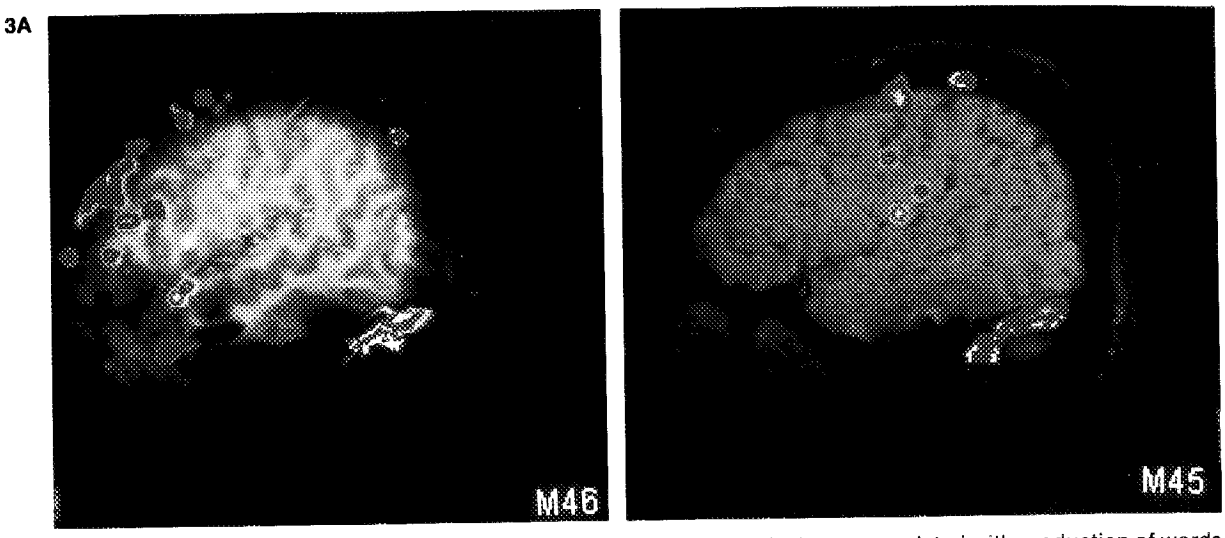

FIG. 3. *Case 1.* Word generation. Signal changes in right **(A)** and left **(B)** hemispheres associated with production of words from a letter given by patient in response to request of examiner.

eration produced signal intensity changes ≤6% in 2 patients; in 1 patient, motion was noted during the lip and tongue movement tasks.

The regions of activation were different for each task (Table 1). A smaller region of change was observed in the same location in the ipsilateral hemisphere. Signal intensity changes were observed with the sequential finger movement task in regions anterior and posterior to the central sulcus in the contralateral and, to a lesser extent, the ipsilateral hemisphere (Fig. 1). Lip and tongue movement in case 1 produced signal changes ventral to the central sulcus and inferior to the region activated by solitary finger movement in both hemispheres (Fig. 2). Word generation produced activation anterior and posterior to central gyrus and in parietal lobe bilaterally (Fig. 3).

DISCUSSION

We showed that FMRI techniques are sensitive to changes in tissue relaxation properties in brain produced by motor tasks involving fingers, lips, and tongue and by word generation task in patients with CPS. To our knowledge, analysis of FMRI in epilepsy patients has not been reported previously.

The magnitude of change in the patients was not appreciably different from that reported previously in normal subjects. We noted no effect of medication or of proximity of a seizure focus. The uniformity of change suggests that in patients with CPS, BF response to activation of cerebral neurons is not affected by the abnormalities in metabolism and BF that have been described in patients with epilepsy. These abnormalities include foci of hypometabolism interictally (Engel et al., 1991), foci of hypermetabolism during ictus (Engel et al., 1991), and foci of hypoperfusion interictally (Berkovic et al., 1991). These results should be considered preliminary, however, because of the small sample size and number of tasks studied.

The limitations of this pilot study are as follows. The number of slices obtained in the patients was limited by computer capacity; therefore, all areas of activations may not have been identified. Spatial resolution was not optimized. Sample size was too limited to allow definite conclusions on effect of handedness and dominant and nondominant hemisphere responses. Tasks and image processing may be refined to provide greater specificity in activated regions. The linkage between regions with increased signal intensity and the regions of increased neuronal activation is not yet proven. The methods we used to determine the anatomic localization of the activated areas are subject to observer bias and inaccuracy. However, improved signal processing techniques, experimental design, and processing speed are the subject of research and development efforts.

The present study suggests that with technologic refinement FMRI may provide a widely available tool to supplement invasive mapping techniques, such as operative cortical stimulation mapping and the intracarotid amobarbital test, currently used in epilepsy patients. The anatomic–functional correlations provided by invasive methods may be obtainable preoperatively without risk with FMRI. Furthermore, FMRI may permit more complex and complete brain mapping (Mueller and Morris, 1993).

Acknowledgment: This work was supported by Grant No. CA 41464 from the National Institute of Health. We thank Dr. J. R. Binder for helpful discussions.

REFERENCES

Bandettini P, Wong EC, Hinks RC, Tikofsky RS, Hyde JS. Time course EPI of the human brain function during task activation. *Magn Reson Med* 1992;25:390–7.

Bandettini PA, Jesmanowicz A, Wong EC, Hyde JS. Processing strategies for time-course data sets in functional MRI of the human brain. *Magn Reson Med* 1993;30:1.

Belliveau JW, Kennedy DN, McKinstry RC, et al. Functional mapping of the human visual cortex by magnetic resonance imaging. *Science* 1991;254:716–9.

Berkovic SF, Newton MR, Rowe CC. Localization of the epileptic focus using SPECT. In: Lüders H, ed. *Epilepsy surgery*, New York: Raven Press, 1991:251–6.

Blamire AM, McCarthy G, Gruetter R, et al. Echo-planar imaging of the left inferior frontal lobe during word generation. *Book of abstracts, 11th annual meeting*. Berlin: Society for Magnetic Resonance Imaging in Medicine, 1992:1834.

Engel J Jr., Henry TR, Risinger MW. The role of position emission tomography in the presurgical evaluation of temporal lobe epilepsy. In: Lüders H, ed. *Epilepsy surgery*, New York: Raven Press, 1991;231–41.

Mueller WM, Morris GL. Intraoperative and extraoperative identification of eloquent brain using stimulation mapping. *Neurosurg Clin North Am* 1993;4:217–22.

Ogawa S, Lee TM, Nayak AS, Glynn P. Oxygenation-sensitive contrast in magnetic resonance image of rodent brain in high magnetic fields. *Magn Reson Med* 1990;14:68–78.

Ogawa S, Tank DW, Menon R, et al. Intrinsic signal changes accompanying sensory stimulation: functional brain mapping using MRI. *Proc Natl Acad Sci USA* 1992;89:5951–5.

Rao SM, Bandettini P, Wong EC, et al. Gradient-echo EPI demonstrates bilateral superior temporal gyrus activation during passive word presentation. *Book of abstracts, 11th annual meeting*. Berlin: Society for Magnetic Resonance in Medicine, 1992:1827.

Rao SM, Binder JR, Bandettini PA, et al. Functional magnetic resonance imaging of complex human movements. *Neurology* 1993;43:2311–8.

Shulman RG, Blamire AM, Rothman DL, McCarthy G. Nuclear magnetic resonance imaging and spectroscopy of human brain function. *Proc Natl Acad Sci USA* 1993;90:3127–33.

Wong EC, Bandettini PA, Hyde JS. Echo-planar imaging of the brain using a three axis coil. *Book of abstracts, 11th annual meeting*. Berlin: Society for Magnetic Resonance in Medicine, 1992*a*:105.

Wong EC, Boskamp E, Hyde JS. A volume optimized quadrature elliptical endcap birdcage brain coil. *Book of Abstracts, 11th annual meeting*. Berlin: Society for Magnetic Resonance in Medicine, 1992*b*:4015.