Localization of the Cortical Response to Smiling Using New Imaging Paradigms with Functional Magnetic Resonance Imaging

Arun K. Gosain, M.D., Rasmus M. Birn, Ph.D., and James S. Hyde, Ph.D.

Milwaukee, Wis.

Functional magnetic resonance imaging (fMRI) can serve to localize activity in the cerebral cortex. The present study was performed to develop a quantitative means of describing the cortical location activated during voluntary smiling in multiple subjects and to determine whether this location is specific to smiling when compared with other motor tasks. Five human subjects were instructed to smile or to tap the fingers of both hands. Both tasks were performed in a blocked-trial paradigm that consisted of alternating 15-second blocks of a repetitive motor task and 15 seconds of rest. Smiling was also performed as an event-related paradigm in which the subject smiled briefly once every 15 seconds for 20 repetitions that were combined to produce an average response to a single smile. A series of 300 images was acquired using an echo-planar imaging sequence (24-cm field of view; 5-mm slice thickness; repetition time/echo time, 1000/27.2 msec). Each subject's three-dimensional brain images were transformed to Talairach coordinates by stretching or compressing the brain images to fit the standard brain as defined in the Talairach atlas. This allowed data from five subjects to be combined for a numeric description. Functional activation maps acquired by use of the event-related paradigm contained significantly fewer motion artifacts than maps acquired with the blocked-trial paradigm, allowing better visualization of functionally active areas. Three-dimensional Talairach coordinates to describe the locations of peak cortical activity after smiling and finger tapping were established. These coordinates were consistent among subjects. During smiling, statistically significant activation was seen in the motor cortex, primarily along the precentral sulcus; this was inferior and anterior to the region that was associated with finger tapping. This study demonstrates that motion artifacts associated with traditional blocked-trial fMRI protocols can be overcome by employing an event-related paradigm to obtain an average response from a single smile. With the implementation of new imaging paradigms with fMRI, an area of the cerebral cortex has been identified that is specifically activated during voluntary smiling, and remains consistent among subjects. Quantification of fMRI data represents a powerful tool by which to study the cortical response to motor activity and to monitor possible alteration in this activity after injury or surgery. When combined with biofeedback therapy, this technique may help to improve the outcome of facial reanimation procedures in the future. (*Plast. Reconstr. Surg.* 108: 1136, 2001.)

Facial expression represents a delicate balance between relaxation and contraction of numerous facial muscles. Both motor and emotional components are involved in the cortical control of these activities. The ability to image cortical control of smiling has several implications. Imaging would facilitate cortical mapping for specific motor activities. It would also serve to detect subtle changes in this map, or cortical plasticity, that may occur after injury or surgery. Functional magnetic resonance imaging (fMRI) has been used as a noninvasive tool locating specific brain functions for almost 10 years.[1–4] It has been used to investigate the neuronal control of a variety of tasks from motor, auditory, and visual processing to cognitive tasks.[5–7] The mapping of different regions of cortical activation during various motor tasks (known as somatotopic mapping) has been done previously by use of direct electrical stimulation.[8] Therefore, it is already known that voluntary smiling is controlled in a slightly different region in the brain compared with finger tapping. This difference, or somatotopy, has not yet been observed with fMRI. Voluntary smiling on command is not the same as emotionally activated smiling. However, the immediate outcome of facial reanimation surgery in

From the Department of Plastic and Reconstructive Surgery and the Department of Biophysics, Medical College of Wisconsin. Received for publication September 15, 2000; revised December 19, 2000.

Presented at the 79th Annual Meeting of the American Association of Plastic Surgeons, in Laguna Niguel, California, on May 8, 2000.

patients with facial paralysis is to restore voluntary control to facial muscles activated during smiling. It is important to first establish the feasibility of localizing the specific region of activation from voluntary smiling before progressing to more complex studies such as cortical plasticity and pathways activated during emotionally activated smiling. Unlike positron emission topographic scans, fMRI is capable of measuring and mapping brain function without the use of contrast materials.[9]

The present study uses blood oxygenation level-dependent fMRI (BOLD-fMRI) to investigate the response of the cerebral cortex to voluntary muscular activity. This technique can be used to investigate cortical control of smiling, thereby identifying sites in the motor cortex that are activated during smiling by a paradigm that is presumed to contain no emotional components. The physiologic basis of BOLD-fMRI is shown in Figure 1. After the onset of a voluntary task, there is an increased neuronal activity in a particular area of the cerebral cortex corresponding to the task. This results in an increased metabolic rate of the active neurons, leading to vasodilatation and subsequent increase in blood flow to the region activated.[10–13] The amount of oxygen in the blood vessels delivered to the site of activation exceeds what is needed metabolically, thereby increasing the local level of oxyhemoglobin and decreasing the local level of deoxyhemoglobin.[14] Deoxyhemoglobin is slightly paramagnetic, and oxyhemoglobin is slightly diamagnetic.[15] This magnetic difference can be detected with magnetic resonance imaging,

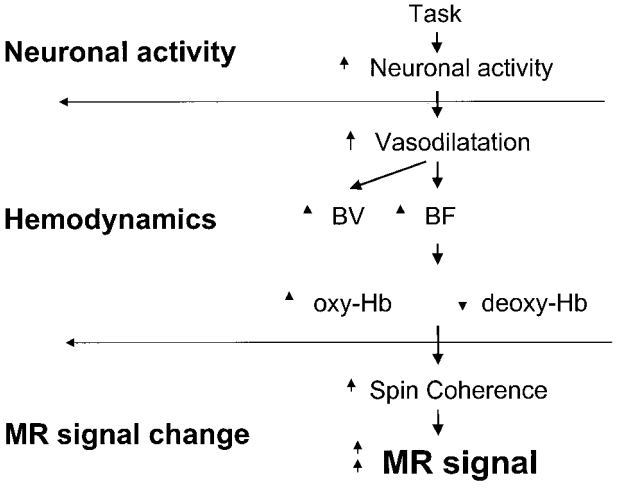

FIG. 1. The physiologic basis of the BOLD-fMRI response. *BV*, blood volume; *BF*, blood flow; *oxy-Hb*, oxyhemoglobin; *Deoxy-Hb*, deoxyhemoglobin.

with a decrease in the presence of a paramagnetic substance resulting in signal increase.[15–18]

Investigation of tasks involving movement of bone or tissue near the region of the brain being imaged has resulted in significant image artifacts. Examples of these have been gross motor movements, overt word production, and swallowing. Movement of the jaw, ocular muscles, and facial muscles has also resulted in significant image artifacts.[19–21] Blocked-trial paradigms, in which motor tasks are repeated for a set block of time followed by a set period of rest, have for a long time been the standard BOLD-fMRI protocol (Fig. 2, *above*).[22] However, blocked-trial paradigms yield conflicting information in separating that component of the magnetic resonance signal that results from motion and that which results from neuronal activation, especially when the motion is associated with the performance of the task. To overcome these image artifacts and enable one to acquire fMRI images reflecting true neuronal activity, an event-related imaging paradigm was developed (Fig. 2, *below*). An event-related paradigm involves performing a task (or presenting a stimulus) for only brief periods of time, separated by a designated period of rest. The resultant magnetic resonance signal contains both motion artifacts and the ideal BOLD response. However, the BOLD response is relatively slow, rising to a peak value 5 to 6 seconds after the onset of the task, and returning to baseline 6 to 7 seconds after cessation of the task, whereas the motion-induced signal change occurs at the same time as the smiling task. The ideal BOLD response can be calculated from the magnetic resonance signal either by ignoring the time points occurring during the motion or, more accurately, by subtracting the expected motion artifact.

The present study was performed to develop a quantitative means of describing the cortical location achieved during voluntary smiling, to demonstrate if the location is specific to voluntary smiling as compared with an unrelated motor task, and to confirm whether the anatomical regions of cortical activation are consistent among multiple subjects.

METHODS

Five human volunteers were studied by use of protocols approved by the Institutional Review Board of the Medical College of Wisconsin. Three sets of echo-planar magnetic resonance images were acquired during voluntary

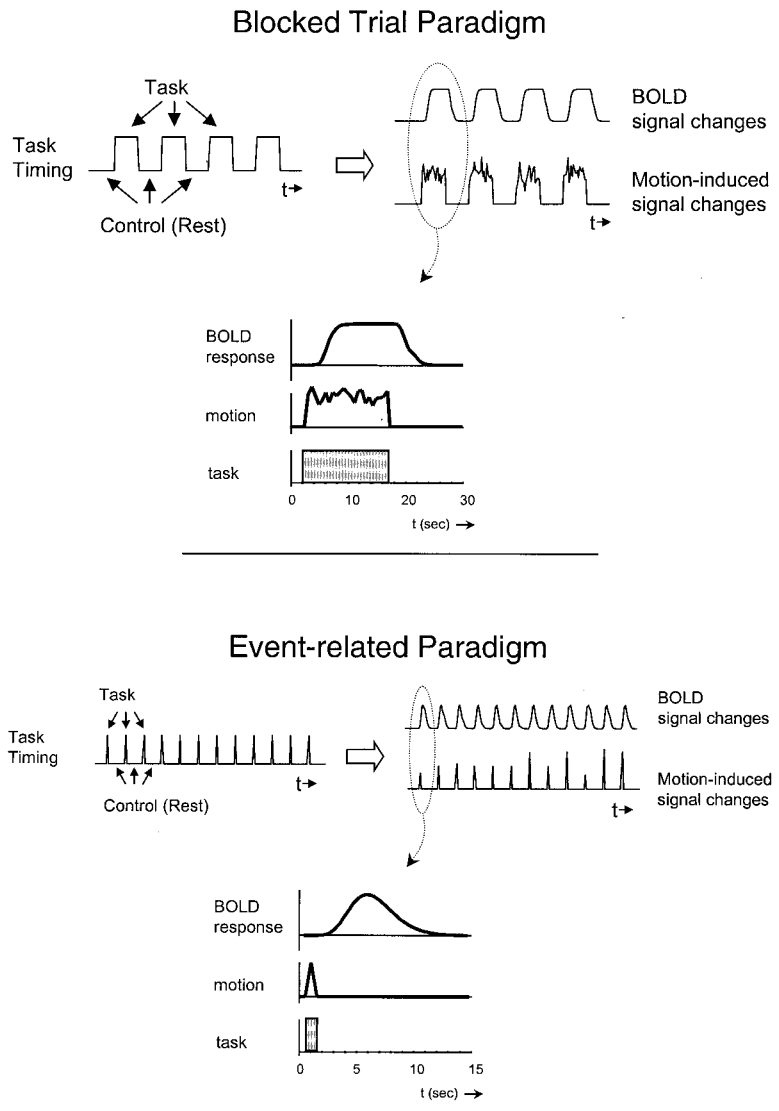

FIG. 2. (*Above*) Blocked-trial paradigm. A specified motor task is repeated for a set block of time followed by a set period of rest, resulting in BOLD signal changes and motion-induced signal changes on magnetic resonance imaging. Because the two signal changes overlap in time, it is difficult to separate which component of the magnetic resonance signal represents the BOLD cortical response and which component results from motion. (*Below*) An event-related paradigm. A motor task is performed for only a brief period of time, separated by a designated period of rest. BOLD signal changes are delayed relative to the motion-induced signal changes after the task.

motor activity in each subject. Both a blocked-trial paradigm consisting of a 15-second repetitive task followed by 15 seconds of rest and an event-related paradigm consisting of a single task briefly performed every 15 seconds were used. Twenty repetitions of each task were performed, with voluntary tasks consisting of either smiling or bilateral finger tapping. The brief smiling task consisted of a single smile, whereas the brief finger-tapping task consisted of a single tap, touching the thumb to each finger once. These 20 episodes were later combined to produce an average response to a single smile. Images from eight slices of the brain were obtained each second by use of a rapid echo-planar magnetic resonance imaging technique with an in-plane resolution of 3.75 × 3.75 mm. A total of 300 images in time of each slice were obtained from each subject (matrix size, 64 × 64; field of view, 24 cm; slice thickness, 5 mm; repetition time, 1000 msec; echo time, 27.2 msec; field strength, 3 Tesla).

Regions of cortical activity were detected by correlating the signal intensity time course within each pixel with a function representing the ideal BOLD response.[22] In previous studies, it has been found that a gamma-variate function closely fit the observed BOLD-fMRI signal change.[23] The theoretical expected response to a series of repeated task performances was obtained by convolving a function representing the stimulus timing (when the task was performed) with the gamma-variate function. The correlation analysis then determines in what regions of the brain the signal changes in this pattern. Motion artifacts were reduced in the event-related paradigm both by realigning the images in the time course and by removing large signal changes occurring during the task performance. This removal was accomplished by identifying a pixel, typically at the edge of the brain, with large signal changes (significantly greater than the baseline noise) during the task and only small signal changes at other times. This time course was used as an additional regressor in the correlation analysis.[22,24] An example of subtracting motion artifact from the observed BOLD signal is illustrated in Figure 3. The large triangular spike in the observed BOLD signal occurred during the task and is part of the convolution. This triangular signal was significantly greater than baseline noise and was identified as motion artifact. Subtraction of motion artifact from the observed signal resulted in the ideal BOLD signal. Because different slices were acquired at different points in time, a separate motion regressor was used for each slice.

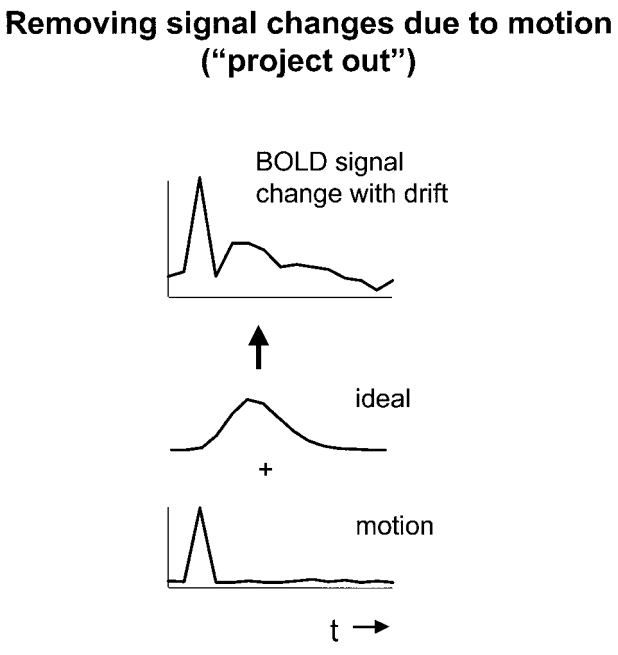

FIG. 3. The BOLD-fMRI signal shows drift from the ideal BOLD response because of associated motion artifact. In an event-related paradigm, the ideal BOLD response can be calculated from the BOLD-fMRI signal by subtracting the expected motion artifact.

A functional activation map was generated by assigning colored regions according to the amplitude of the magnetic resonance signal that correlated with the assigned task. A BOLD-fMRI response that correlated closely with the task was designated by a color in the yellow-red spectrum, and a BOLD-fMRI response that was negatively correlated with the task (where the signal decreased after task performance) was designated by a color in the blue spectrum. These latter changes are not typically observed as a result of neuronal activity and are most likely the result of image artifacts such as motion. A statistical threshold was applied to these maps such that only regions with statistically significant signal changes matching the expected BOLD response are displayed.

Higher resolution anatomical scans were obtained and used to transform each subject's three-dimensional brain image to Talairach coordinates. Talairach coordinates are a means of aligning the brain by means of identification of anatomical subcortical structures and compressing or stretching the brain image to accommodate a standard brain size. This is done to facilitate the comparison between two or more brain maps. Detected regions of activation were averaged across the five subjects.

RESULTS

Specific regions of activation in the primary and supplementary motor cortexes were clearly identified in all five subjects studied. The BOLD-fMRI response to a blocked-trial smiling paradigm is demonstrated after thresholding (Fig. 4, *left*). Activity outside the cerebral cortex represents a motion artifact. Within the cerebral cortex, only a few points demonstrate the expected response; these are shown toward the red end of the spectrum after thresholding. Negative signal changes, which are not characteristic of BOLD signal changes, fall in the blue range of the spectrum and therefore do not reflect the neuronal activity associated with smiling. The BOLD-fMRI response to an event-related smiling paradigm is also demonstrated (Fig. 4, *right*). Activation is now much more specific to the anatomic re-

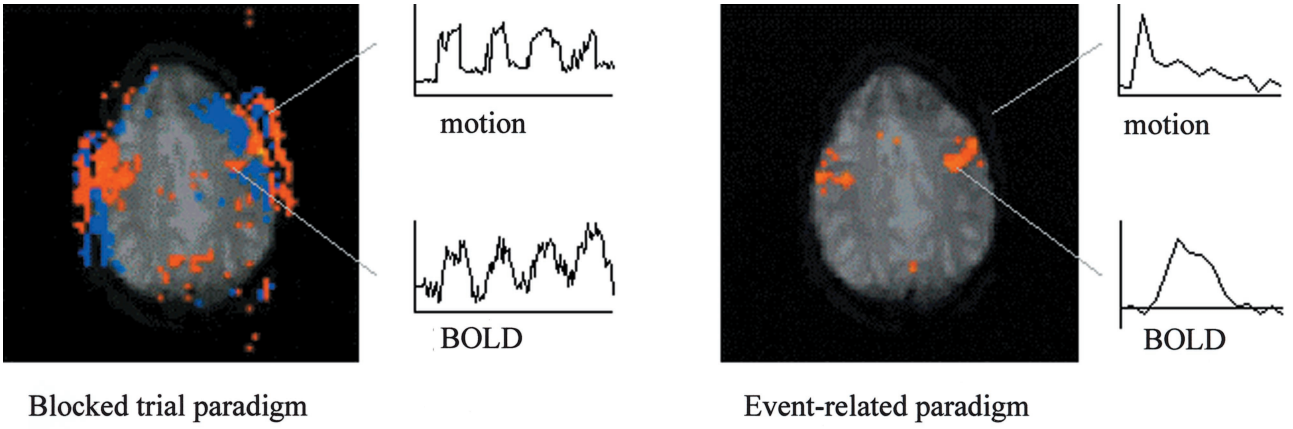

FIG. 4. (*Left*) The BOLD-fMRI response to a blocked-trial smiling paradigm is demonstrated after threshholding. The expected response falls in the red end of the spectrum after thresholding, and negative signal changes that are not characteristic of BOLD signal changes fall in the blue range of the spectrum after thresholding. Activity outside the cerebral cortex represents motion artifact. Within the cerebral cortex, only a few points demonstrate the expected BOLD response. (*Right*) The BOLD-fMRI response to an event-related smiling paradigm is demonstrated after thresholding. All motion artifact has been cancelled after the known motion is subtracted, resulting in a highly specific BOLD-fMRI response in the designated regions of the cerebral cortex.

gion of the cerebral cortex. The functional activation map shows all motion artifacts to be cancelled after the known motion is subtracted. This results in a highly specific BOLD-fMRI response in the designated regions of the cerebral cortex. Motion artifact with smiling was found to be maximum at time zero when the task was initiated and was minimal by 3 seconds after the task when the BOLD-fMRI response was peaking. There was minimal motion artifact after finger tapping because tapping the fingers does not result in significant head movement. The BOLD-fMRI response peaked 3 seconds after initiation of the task. This temporal difference in the signal response to motion and the BOLD signal change was used to distinguish motion artifacts from signal changes representing neuronal activity.

A series of axial images taken during an event-related smiling paradigm in one subject is demonstrated, with the axial images arranged from inferior to superior (Fig. 5, *above*). Activated regions are indicated in color. Most of the BOLD-fMRI activity was located on axial images 3 and 4. Comparable axial images taken during an event-related finger tapping paradigm in the same subject are also shown (Fig. 5, *below*). The majority of the task-specific BOLD-fMRI response was seen in axial images 4 through 6, which was superior in anatomic location to the BOLD-fMRI response after single-trial smiling. Axial reconstruction averaging the peak activity in all five subjects demonstrates the central focus for smiling (Fig. 6, *above*, *left*) to be located anterior to that for finger tapping (Fig. 6, *above*, *right*). Coronal reconstruction of peak activity demonstrates the central focus for smiling (Fig. 6, *below*, *left*) to be located inferior to that for finger tapping (Fig. 6, *below*, *right*).

This information was translated into Talairach coordinates to localize cortical activity in three dimensions. Numeric coordinates were assigned to the areas of peak activity on the basis of a right or left axis, a posterior-anterior axis, and a superior-inferior axis. Mean data characterizing smiling and finger tapping by Talairach coordinates localized both activities to the region of the precentral gyrus (Table I). However, peak activity for motor control of smiling was located anterior and inferior to peak activity for motor control of finger tapping.

DISCUSSION

The use of fMRI to image activity in the cerebral cortex of the human brain was first reported in 1992.[1–4] Since then, numerous investigators have reported on the use of fMRI to localize cortical activity in humans.[25] Early fMRI studies of the motor cortex focused on validating the results by comparing with other imaging modalities such as positron emission topography[9] or direct electrical stimulation.[26] The somatotopic organization has been studied in the primary cortex[27] and subcortical areas[28] and in specialized regions of the primary motor cortex.[29] Other studies have focused on

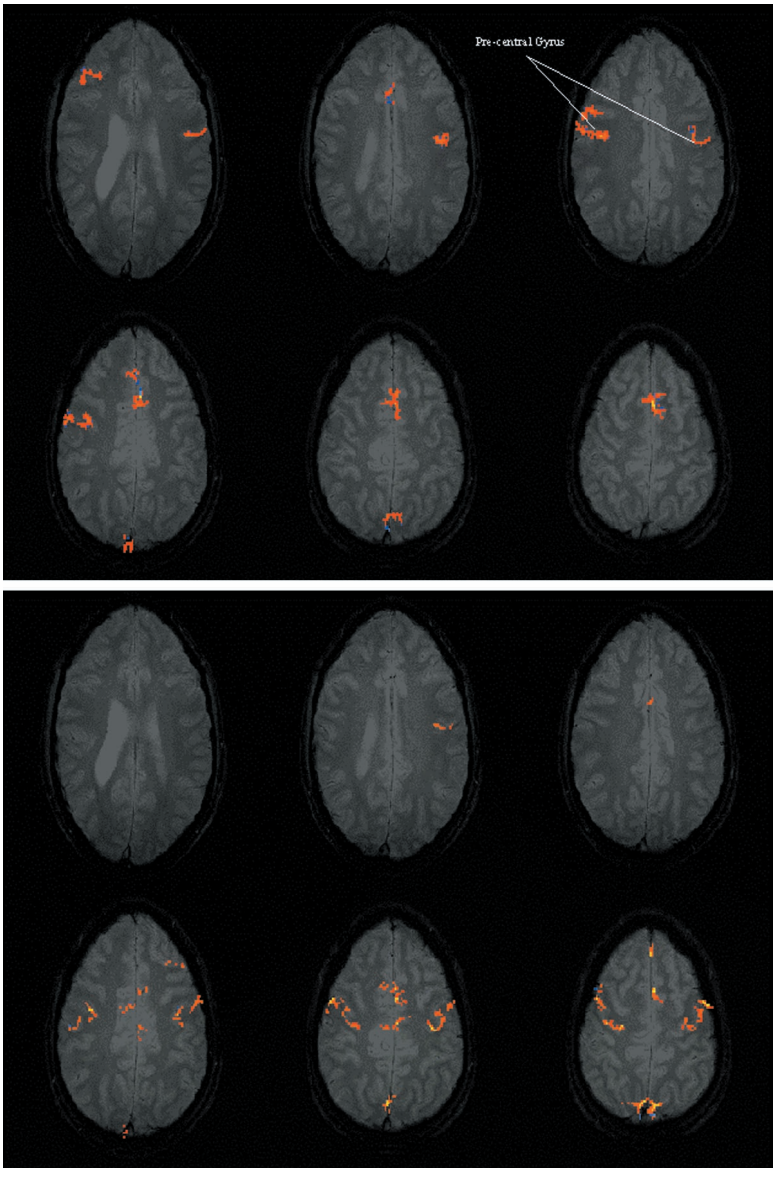

FIG. 5. (*Above*) A series of axial images taken during an event-related smiling paradigm in one subject is demonstrated, with the axial images arranged from inferior (*upper left*) to superior (*lower right*). Most of the BOLD-fMRI activity is located on axial images 3 and 4 in the region of the precentral gyrus. (*Below*) A comparable series of axial images taken during an event-related finger tapping paradigm in one subject is demonstrated. The majority of the task-specific BOLD-fMRI response is located on axial images 4 through 6, superior to that identified after smiling in the same subject.

the laterality of motor control.[30] More recent studies have demonstrated cortical plasticity in the motor cortex after hemiparesis or hemispherectomy.[31–34]

Previously, such imaging protocols could only be performed by use of positron emission topographic imaging. Positron emission topography remains the imaging technique of choice for obtaining specific physiologic information about the cerebral cortex, such as glucose delivery and neuronal metabolism.[35] However, fMRI has several advantages over positron emission topographic scanning: fMRI has higher temporal and spatial resolution than does positron emission topographic scanning; most hospitals have greater accessibility and availability to magnetic resonance imaging than to positron emission topography; fMRI does not require use of a radioisotope contrast material, whereas positron emission topography does; and

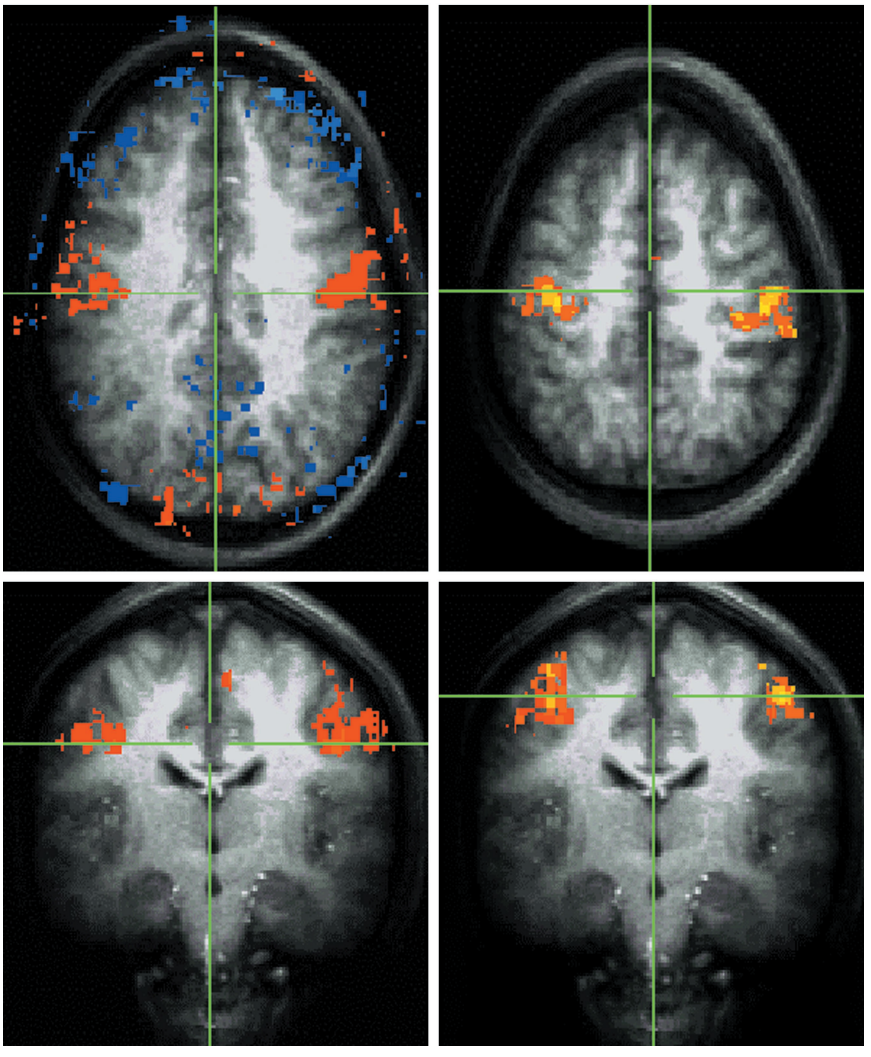

FIG. 6. Axial reconstruction averaging the peak activity in all five subjects demonstrates the central focus for smiling (*above, left*) to be located anterior to that for finger tapping (*above, right*). Coronal reconstruction averaging the peak activity in all five subjects demonstrates the central focus for smiling (*below, left*) to be located inferior to that for finger tapping (*below, right*).

TABLE I
Regions of Activation

Task	Talairach Coordinates	Anatomical Name
Smiling	−46 (R), 8 (P), 38 (S)	Right precentral gyrus
	50 (L), 11 (P), 37 (S)	Left precentral gyrus
Finger tapping	−37 (R), 21 (P), 50 (S)	Right precentral gyrus
	44 (L), 23 (P), 50 (S)	Left precentral gyrus

R, right axis; P, posterior-inferior axis; S, superior-inferior axis; L, left axis.

fMRI is considered to be noninvasive and is therefore without significant health risks. This enables a subject to be scanned a repeated number of times, allowing changes in the neuronal activity to be tracked over long periods of time. This advantage has been used in fMRI studies of motor learning, such as the learning of complex new finger movements.[36]

In the past, it has been difficult to distinguish motion artifacts from fMRI signal changes in images, especially when the motion occurs as a result of the task being performed. This is because fMRI relies on detecting relatively small signal changes over time, and small amounts of subject movement can result in large signal changes. As a result, subject motion is particularly detrimental to fMRI studies. This difficulty has recently been examined and reduced by use of an event-related paradigm instead of the traditional blocked-trial paradigm.[24] However, limitations of fMRI remain. Functional contrast (the ability to detect func-

tionally active areas) is usually increased by use of a high magnetic field strength and by use of imaging techniques that are sensitive to small changes in the magnetic environment. These latter techniques are necessary to detect the small difference in magnetism between oxyhemoglobin and deoxyhemoglobin, the concentrations of which change during increased neuronal activity. Unfortunately, these sequences are also highly sensitive to other sources of magnetic field distortions that are more pronounced at high field strengths. Regions near the base of the brain in close proximity to bone cavities, which induce magnetic field distortions, are therefore difficult to image. Although greater imaging time may be required, recent advances have been made that may help to recover lost signal in these areas.[37–39] The imaging paradigm proposed in the present study is one solution by which to localize activity in these cortical regions during a task that involves a brief movement.

CONCLUSIONS

We have demonstrated that motion artifacts associated with traditional blocked-trial fMRI protocols can be overcome by employing an event-related paradigm to obtain an average response from a single smile. With the implementation of new imaging paradigms using fMRI, an area of the cerebral cortex has been identified that is specifically activated during voluntary smiling and remains consistent among subjects. Quantification of fMRI data represents a powerful tool by which to study the cortical response to motor activity and to monitor possible alteration in this activity after injury or surgery. Furthermore, the ability to localize those regions in the cerebral cortex that are responsible for the motor control of smiling independent of emotional input may have significant therapeutic value. Biofeedback therapy is often used after facial reanimation surgery to maximize spontaneity and to aid in the development of facial symmetry during smiling. Monitoring the cortical response and providing feedback to the individual during smiling may help to achieve the goal of an appropriate and symmetric smile after facial reanimation surgery. Recent technologic advances have made it possible to acquire the magnetic resonance images, compute the location of activated regions, and display this information in real time.[40] Synkinesis, involving the uncontrolled activation of numerous facial muscles when the patient attempts to smile, remains an unsolved problem after facial reanimation surgery. Should fMRI help patients to distinguish cortical tracts specifically activated during voluntary smiling versus those tracts activated during synkinesis, it would provide a major advance in the surgical management of facial paralysis. The information from such biofeedback treatments may serve as a potential indicator of a patient's ability to integrate the emotional and motor control needed to produce spontaneous facial expression after facial nerve injury or surgery.

Arun K. Gosain, M.D.
Department of Plastic and Reconstructive Surgery
Medical College of Wisconsin
9200 West Wisconsin Avenue
Milwaukee, Wis. 53226
agosain@mcw.edu

ACKNOWLEDGMENT

We would like to thank Phillippe A. Capraro, M.D., for his assistance in preparing the manuscript.

REFERENCES

1. Bandettini, P. A., Wong, E. C., Hinks, R. S., et al. Time course EPI of human brain function during task activation. *Magn. Reson. Med.* 25: 390, 1992.
2. Frahm, J., Bruhn, H., Merboldt, K. D., and Hanicke, W. Dynamic MR imaging of human brain oxygenation during rest and photic stimulation. *J. Magn. Reson. Imaging* 2: 501, 1992.
3. Kwong, K. K., Belliveau, J. W., Chesler, D. A., et al. Dynamic magnetic resonance imaging of human brain activity during primary sensory stimulation. *Proc. Natl. Acad. Sci. U.S.A.* 89: 5675, 1992.
4. Ogawa, S., Tank, D. W., Menon, R., et al. Intrinsic signal changes accompanying sensory stimulation: Functional brain mapping with magnetic resonance imaging. *Proc. Natl. Acad. Sci. U.S.A.* 89: 5951, 1992.
5. Binder, J. Functional magnetic resonance imaging of language cortex. *Int. J. Imaging Systems Technol.* 6: 280, 1995.
6. Cohen, M. S., and Bookheimer, S. Y. Localization of brain function using magnetic resonance imaging. *Trends Neurosci.* 17: 268, 1994.
7. Schulman, R. G., Blamire, A. M., Rothman, D. L., and McCarthy, G. Nuclear magnetic resonance imaging and spectroscopy of human brain function. *Proc. Natl. Acad. Sci. U.S.A.* 90: 3127, 1993.
8. Penfield, W., and Boldrey, E. Somatic motor and sensory representation in the cerebral cortex of man as studied by electrical stimulation. *Brain* 60: 389, 1937.
9. Ramsey, N. F., Kirkby, B. S., Van Gelderen, P., et al. Functional mapping of human sensorimotor cortex with 3D BOLD fMRI correlates highly with H2(15)O PET rCBF. *J. Cereb. Blood Flow Metab.* 16: 755, 1996.
10. Roy, C. S., and Sherrington, C. S. On the regulation of the blood supply of the brain. *J. Physiol. (Lond.)* 11: 85, 1890.
11. Phelps, M. E., Kuhl, D. E., and Mazziota, J. C. Metabolic

mapping of the brain's response to visual stimulation: Studies in humans. *Science* 211: 1445, 1981.
12. Frostig, R. D., Lieke, E. E., Ts'o, D. Y., and Grinvald, A. Cortical functional architecture and local coupling between neuronal activity and the microcirculation revealed by in vivo high-resolution optical imaging of intrinsic signals. *Proc. Natl. Acad. Sci. U.S.A.* 87: 6082, 1990.
13. Belliveau, J. W., Kennedy, D. N., Jr., McKinstry, R. C., et al. Functional mapping of the human visual cortex by magnetic resonance imaging. *Science* 254: 716, 1991.
14. Fox, P. T., and Raichle, M. E. Focal physiological uncoupling of cerebral blood flow and oxidative metabolism during somatosensory stimulation in human subjects. *Proc. Natl. Acad. Sci. U.S.A.* 83: 1140, 1986.
15. Brindle, K. M., Brown, F. F., Campbell, I. D., et al. Application of spin-echo nuclear magnetic resonance to whole-cell systems: Membrane transport. *Biochem. J.* 180: 37, 1979.
16. Thulborn, K. R., Waterton, J. C., Matthews, P. M., and Radda, G. K. Oxygenation dependence of the transverse relaxation time of water protons in whole blood at high field. *Biochim. Biophys. Acta* 714: 265, 1982.
17. Turner, R., Le Bihan, D., Moonen, C. T., et al. Echoplanar time course MRI of cat brain oxygenation changes. *Magn. Reson. Med.* 22: 159, 1991.
18. Boxerman, J. L., Hamberg, L. M., Rosen, B. R., and Weisskoff, R. M. MR contrast due to intravascular magnetic susceptibility perturbations. *Magn. Reson. Med.* 34: 555, 1995.
19. Birn, R. M., Bandettini, P. A., Cox, R. W., et al. Magnetic field changes in the human brain due to swallowing or speaking. *Magn. Reson. Med.* 40: 55, 1998.
20. Hajnal, J. V., Bydder, G. M., and Young, I. R. Stimulus-correlated signals in functional MR of the brain (Comment). *A.J.N.R. Am. J. Neuroradiol.* 17: 1011, 1996.
21. Yetkin, F. Z., Haughton, V. M., Cox, R. W., et al. Effect of motion outside the field of view on functional MR. *A.J.N.R. Am. J. Neuroradiol.* 17: 1005, 1996.
22. Bandettini, P. A., Jesmanowicz, A., Wong, E. C., and Hyde, J. S. Processing strategies for time-course data sets in functional MRI of the human brain. *Magn. Reson. Med.* 30: 161, 1993.
23. Cohen, M. S. Parametric analysis of fMRI data using linear systems methods. *Neuroimage* 6: 93, 1997.
24. Sakai, K., Hikosaka, O., Miyauchi, S., et al. Transition of brain activation from frontal to parietal areas in visuomotor sequence learning. *J. Neurosci.* 18: 1827, 1998.
25. Mattay, V. S., and Weinberger, D. R. Organization of the human motor system as studied by functional magnetic resonance imaging. *Eur. J. Radiol.* 30: 105, 1999.
26. Yetkin, F. Z., Mueller, W. M., Morris, G. L., et al. Functional MR activation correlated with intraoperative cortical mapping. *A.J.N.R. Am. J. Neuroradiol.* 18: 1311, 1997.
27. Rao, S. M., Binder, J. R., Hammeke, T. A., et al. Somatotopic mapping of the human primary motor cortex with functional magnetic resonance imaging. *Neurology* 45: 919, 1995.
28. Lehericy, S., van de Moortele, P. F., Lobel, E., et al. Somatotopical organization of striatal activation during finger and toe movement: A 3-T functional magnetic resonance imaging study. *Ann. Neurol.* 44: 398, 1998.
29. Kleinschmidt, A., Nitschke, M. F., and Frahm, J. Somatotopy in the human motor cortex hand area. A high-resolution functional MRI study. *Eur. J. Neurosci.* 9: 2178, 1997.
30. Mattay, V. S., Callicott, J. H., Bertolino, A., et al. Hemispheric control of motor function: A whole brain echo planar fMRI study. *Psychiatry Res.* 83: 7, 1998.
31. Graveline, C. J., Mikulis, D. J., Crawley, A. P., and Hwang, P. A. Regionalized sensorimotor plasticity after hemispherectomy fMRI evaluation. *Pediatr. Neurol.* 19: 337, 1998.
32. Cao, Y., D'Olhaberriague, L., Vikingstad, E. M., et al. Pilot study of functional MRI to assess cerebral activation of motor function after poststroke hemiparesis. *Stroke* 29: 112, 1998.
33. Rossini, P. M., Caltagirone, C., Castriota-Scanderbeg, A., et al. Hand motor cortical area reorganization in stroke: A study with fMRI, MEG and TCS maps. *Neuroreport* 9: 2141, 1998.
34. Yoshiura, T., Hasuo, K., Mihara, F., et al. Increased activity of the ipsilateral motor cortex during a hand motor task in patients with brain tumor and paresis. *A.J.N.R. Am. J. Neuroradiol.* 18: 865, 1997.
35. Phelps, M. E. PET: The merging of biology and imaging into molecular imaging. *J. Nucl. Med.* 41: 661, 2000.
36. Birn, R. M., Bandettini, P. A., Cox, R. W., and Shaker, R. Event-related fMRI of tasks involving brief motion. *Hum. Brain Mapp.* 7: 106, 1999.
37. Constable, R. T., and Spencer, D. D. Composite image formation in z-shimmed functional MR imaging. *Magn. Reson. Med.* 42: 110, 1999.
38. Glover, G. H. 3D z-shim method for reduction of susceptibility effects in BOLD fMRI. *Magn. Reson. Med.* 42: 290, 1999.
39. Yang, Q. X., Dardzinski, B. J., Li, S., et al. Multi-gradient echo with susceptibility inhomogeneity compensation (MGESIC): Demonstration of fMRI in the olfactory cortex at 3.0 T. *Magn. Reson. Med.* 37: 331, 1997.
40. Cox, R. W., Jesmanowicz, A., and Hyde, J. S. Real-time functional magnetic resonance imaging. *Magn. Reson. Med.* 33: 230, 1995.