Magnetic Field Changes in the Human Brain Due to Swallowing or Speaking

Rasmus M. Birn, Peter A. Bandettini, Robert W. Cox, Andrzej Jesmanowicz, Reza Shaker

Variations in the magnetic field in the human brain caused by the processes of swallowing or speaking are measured. In both processes, motion of the pharyngeal muscles, especially the tongue and jaw, alter the susceptibility-induced magnetic field distribution at the brain slice being imaged. This leads to image warping, compromising the analysis of a time series of images, such as in functional magnetic resonance imaging (fMRI). These dynamic changes are assessed by acquiring a time series of images using a gradient-echo asymmetric-spin-echo sequence (GREASE), a technique in which two images are acquired for each excitation—one during the gradient echo, and one during the latter part of the spin echo. The NMR phase difference between the two images is a measure of the magnetic field distribution. A series of brain images, acquired with this sequence while the subject either swallows or speaks, indicated negative magnetic field changes of up to 0.087 ppm in the inferior region of the brain for both speaking and swallowing, and in some speech, additional positive changes of up to 0.056 ppm in the frontal region of the brain were indicated.

Key words: magnetic field measurement; dynamic imaging; swallowing; fMRI.

INTRODUCTION

Since 1991, high-speed acquisition of T_2*-weighted magnetic resonance images has been used to study the neuronal control of a variety of tasks from simple finger movements to complex auditory language processing (1–4). The evaluation of the neuronal function associated with certain tasks, such as speaking or swallowing, has been difficult because of large artifacts in the resulting functional images (5, 6). As a result, experimental paradigms have been designed to focus on specific aspects of these tasks. In swallowing, for example, studies have turned to esophageal balloon distension (7) or analyzing only the activity in the motor cortex associated with swallowing (8). For the analysis of language, paradigms that do not involve overt subject motion, such as silent word generation or silent semantic processing with nonverbal responses, have been implemented (9). There are, however, some aspects of the swallowing and speaking processes that cannot be addressed in this manner, such as the neuronal function associated with the movement itself. In addition, many neuropsychological paradigms for functional magnetic resonance imaging (fMRI) would benefit from having the subject vocalize a response. It is therefore important to understand fully the mechanisms that give rise to these artifacts.

The artifacts observed in fMRI of speech or swallowing have commonly been attributed to motion of the subject's head during the imaging study. Although this is certainly an important factor, a large part of the artifact is in fact due to changes in the magnetic field caused by the processes of swallowing and speaking. It is the aim of this study to measure these magnetic field changes. This paper will first present a mechanism by which motions such as speaking and swallowing can cause changes in the magnetic field and will introduce a technique by which these magnetic field changes can be measured throughout the imaging series. This magnetic field mapping technique is then applied to measure the magnetic field changes during both swallowing and speaking, demonstrating that significant magnetic field perturbations are caused by swallowing and speaking, especially in the inferior region of the brain.

BACKGROUND

Both speaking and swallowing involve the coordination of a complex series of movements. In fact, swallowing alone requires 31 pairs of muscles (10). In an fMRI study of speaking or swallowing, this motion would by definition be correlated with the task, and thus one would expect any artifactual signal changes to result from the stimulus-correlated motion of the subject's head (11). Motion correction algorithms, however, have only been partially successful in correcting for this, and artifacts are still observed even with rigorous head restraints. This shortcoming can be explained by some recent experiments that demonstrate that motion outside the FOV near the object being imaged can cause apparent motion of the image, even if the imaged object remains absolutely still (12, 13). This is because the additional presence of an object outside the FOV perturbs the magnetic field in the region being imaged. The magnetic field distortion alters the spatial relationships of the magnetic field to the object being studied, thus causing the image to be warped. When this is correlated with the presentation of the stimulus, then the apparent motion leads to stimulus-correlated signal intensity changes near edges that can be mistaken for signal changes resulting from neuronal activation.

MRM 40:55–60 (1998)

From the Biophysics Institute and Dysphagia Institute (R.S.), Division of Gastroenterology and Hepatology, Department of Medicine, Medical College of Wisconsin, Milwaukee, Wisconsin.

Address correspondence to: Rasmus M. Birn, Biophysics Research Institute, Medical College of Wisconsin, 8701 Watertown Plank Rd., Milwaukee, WI 53226.

Received September 22, 1997; revised March 10, 1998; accepted March 15, 1998.

This work was supported by grants MH51358, NS34798, and DC00669 from the National Institutes of Health.

0740-3194/98 $3.00

Copyright © 1998 by Williams & Wilkins
All rights of reproduction in any form reserved.

The exact form of this warping is dependent on the pulse sequence used for imaging. In echo-planar imaging, a magnetic field distortion causes pixels in the image to shift in the phase-encoding direction by an amount related to the amount of offset in the magnetic field (14). Consequently, the largest signal changes when the object is shifted will occur in regions with a large spatial gradient in signal intensity, such as an edge. A spatial variation in the strength of the magnetic field perturbation, and hence the amount of shift, can cause the image to be stretched or compressed, leading to additional decreases or increases in the signal intensity. These effects were demonstrated in ref. 12 by moving a small vial of water alternately toward and away from a phantom while a series of echo-planar images were being acquired. The resulting images showed corresponding signal changes near the edges in the phase-encoding direction.

Since the magnetic field perturbation increases rapidly as the distance from the object outside the FOV to the image plane is decreased, small movements close to the imaged object can produce the same magnitude of signal change as large movements that are further away. Therefore, even small movements, such as those of the tongue or the jaw during speaking and swallowing, can produce significant changes in the magnetic field in the brain. These magnetic field changes then can produce signal intensity changes on the same order, or higher, than those resulting from the neuronal activation-induced blood oxygenation changes (blood oxygen level dependent (BOLD) signal) (12, 13).

It is possible to obtain a measure of the magnetic field changes by analyzing the NMR phase of the signal. This is because any variation in the magnetic field alters the resonance frequency, causing a phase shift at a given point in time. Using just the phase as a measure of the magnetic field, however, makes the assumption that there are no other influences on the phase, such as motion or flow, throughout the whole imaging scan. A more robust estimate of the changes in B_z can be made by acquiring two images with different echo times. The extra phase acquired in the ΔTE is directly proportional to the magnetic field at that point (15). This technique only makes the assumptions that there are no intra-FOV motion or change in the magnetic field between the two images, a period of time that can be reduced to only 100 ms or less.

This technique can be extended to measure dynamic changes in the magnetic field by alternating the TE for every other image. Consecutive phase images can then be subtracted to produce a time series of magnetic field maps (see Fig. 1).

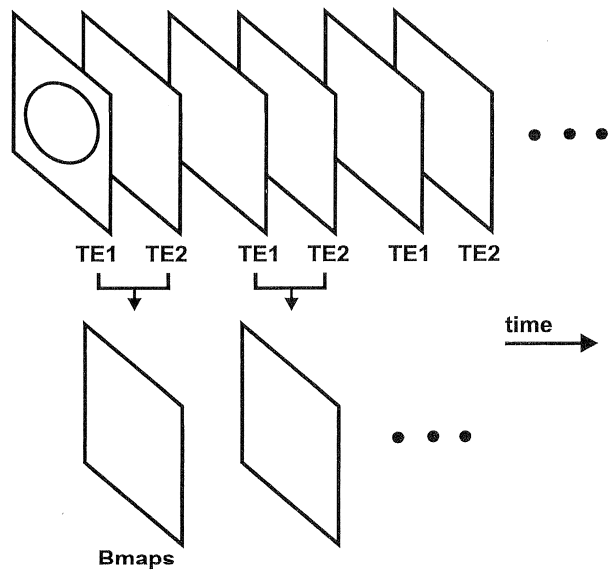

FIG. 1. The technique used to obtain a time series of magnetic field maps. Echo time was varied between 2 values, TE1 and TE2, for every image. Consecutive pairs of phase images are subtracted in the complex domain in order to produce a series of magnetic field maps.

METHODS

Dynamic changes in the magnetic field were measured using a gradient echo asymmetric spin echo (GREASE) sequence (16). In this technique, two images were acquired for each excitation—the first during the gradient echo, and the second after the spin echo, but offset such that the effective echo time of the second image (τ in Fig. 2) is slightly longer than that of the first image (TE_{ge} in Fig. 1). Because the time between the acquisition of the two images with differing echo times is only 100 ms, any errors in the B-field map resulting from motion or changes in the magnetic field in the time between the two images are minimized.

In Study 1, a series of 200 pairs of images was acquired while the subject swallowed once every 10 s. In addition, another series of images was obtained while the subject alternately swallowed and held the position of the larynx in the maximal superior excursion for 5 s, a procedure known as Mendelsohn's maneuver (17, 18), then rested for 5 s. This latter maneuver was done to more accurately assess the magnetic field change during the swallow as well as minimize the chance of intra-FOV motion or changes in the magnetic field between the two images collected at different TEs. In Study 2, the subject alternately spoke the words "one" and "two" once every 5 s during the collection of 200 pairs of echo-planar images. The subject was asked to speak each word slowly and clearly without moving the head.

Both studies were performed on a Bruker Biospec 3T/60 scanner (Bruker Medical, Karlsruhe, Germany) using local head gradient coils (19). The TR for both studies was 200 ms, with a TE of 27.2 ms for the first image and a spin echo time of 109.6 ms. The second image was collected 47.2 ms after the center of the spin echo, resulting in an image with an effective echo time 20 ms greater than the echo time of the first image. It was found that this 20-ms difference in TE provided sufficient dynamic range to visualize the magnetic field change while minimizing (but not completely eliminating) any wrapping of the phase difference. The 180° pulse was applied along an axis perpendicular to the 90° pulse. The bandwidth per pixel in the phase-encoding direction for these 64 × 64 images was 22.1 Hz. Gross head motion in all studies

was reduced by tight foam padding around the subject's head.

A measure of the magnetic field was obtained by computing the difference of successive phase images gathered at the two different echo times. Since these magnetic field maps are based on phase images, the values wrap whenever the phase difference exceeds π or $-\pi$. To correct for this, the computed magnetic field maps were unwrapped using a phase-unwrapping algorithm similar to that described by Hedley *et al.* (20), but employing a region growing algorithm to visit all of the points within the region of interest. Phase values outside the brain image were suppressed by simple threshold of the magnitude image. Since the two images used to produce this magnetic field map are warped as a result of the magnetic field perturbation, the magnetic field map calculated from these two images is also be warped. However, it is warped in exactly the same way as the magnitude image and thus still describes the magnetic field at every point in the (warped) image. To correct for this distortion in the B-field map and report the magnetic field distortions with respect to a normal, unwarped, brain image, each of the two complex images collected at the two different echo times was unwarped by shifting every pixel in the phase-encoding direction by an amount corresponding to the magnetic field value at that point (21, 22).

$$I_{warped}(x, y) = |F'_x(y)| e^{-iTE\Delta\omega(x, F_x(y))} M_T(x, F_x(y)) \quad [1]$$

$$I_{corrected}(x, y) = \frac{1}{|F'_x(y - \Delta y)|} I_{warped}(x, y - \Delta y) \quad [2]$$

$$\Delta y = y - F_x^{-1}(y)$$

where $I_{warped}(x, y)$ is the warped image, $I_{corrected}(x, y)$ is the image after correction, $M_T(x, y)$ is the transverse magnetization, $\Delta\omega$ is the magnetic field perturbation, and TE is the echo time. $F_x(y)$ describes the warping in the phase encoding (y) direction, which depends on the strength of the magnetic field perturbation,

$$F_x(y) = inverse_y\{y + c\Delta\omega(x, y)\} \quad [3]$$

where $inverse_y$ denotes the functional inverse with respect to y, and

$$c = (\text{time between scan lines}) \cdot \frac{FOV_y}{2\pi} \quad [4]$$

This warping function can also be written in terms of the shift of each pixel, Δy, as shown in Eq. [2]. $F'_x(y)$ describes the signal decreases when the image is stretched, and the signal increases when it is compressed. The shifting was performed in Fourier space by multiplying the Fourier transform of the image by appropriate phase factors (θ), specifically,

$$\theta(x, y) = \frac{\Delta\phi(x, y)}{\Delta TE} \cdot (\text{time between scan lines}) \quad [5]$$

where $\Delta\phi$ is the phase difference between the two images acquired with an echo time difference of ΔTE. This allowed subpixel shifts to be performed. Any signal decrease or increase resulting from stretching or compressing the image was also corrected.

The phase images of the two corrected images were then subtracted by multiplying the complex conjugate of the first image by the second image and taking the phase of the result, in order to yield the final corrected magnetic field map (see Figure 3). Changes in the magnetic field were computed by subtracting an average of the magnetic field values during the "rest" from an average of the magnetic field values during speech or swallowing.

RESULTS

For Study 1 (magnetic field changes during swallowing), the greatest magnetic field change of approximately −9.5 Hz occurred in the inferior region of the brain, decreasing rapidly to −1.3 Hz at the superior edge (see Fig. 4). This maximal magnetic field change corresponds to a −0.075-ppm change that causes a 0.43-pixel shift in the final image. The exact amount of signal change in the magnitude image as a result of this shift depends on the spatial gradient in signal intensity. In a region where there is a large spatial gradient in signal intensity, such as the edge of the imaged object, this shift could thus lead to a 40% change in signal intensity. Inside the brain, the spatial variation in signal intensity is only 10–15%, and the shift leads to a 4–6% signal change. Therefore, the magnetic field artifact from swallowing appears predominantly at the edge or in sulci of the brain, where the greatest spatial variation in signal intensity exists.

For Study 2 (magnetic field changes during speaking the words "one" and "two"), the largest magnetic field change again occurred in the inferior

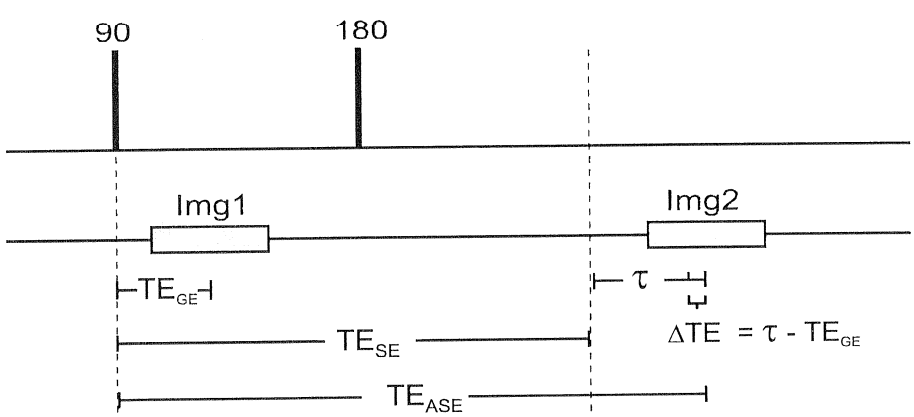

FIG. 2. GREASE sequence used to acquire two images with different echo times necessary to obtain a measure of the magnetic field. The first image was collected during the gradient echo, and the second image was collected during the spin echo but offset such that the effective echo time of the second image, τ, is slightly longer than the echo time of the first image, TE_{GE}.

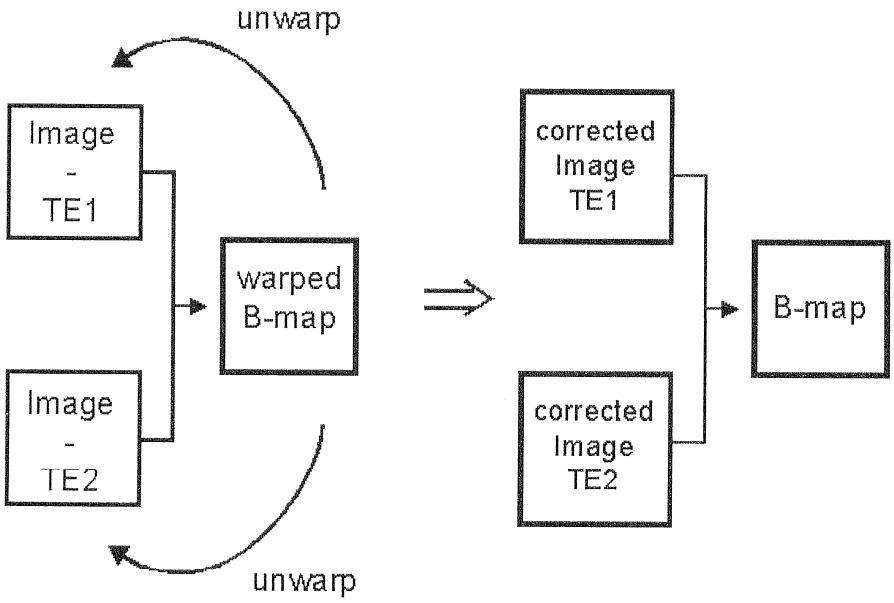

FIG. 3. Steps performed to produce correct magnetic field maps. The measure of the magnetic field obtained from the two images at different echo times is warped in the phase-encoding direction, since it is calculated from two warped images. This map is used to unwarp each of the original images. The corrected images are then combined to produce a corrected magnetic field map.

region of the brain, decreasing rapidly in the superior and lateral directions (see Fig. 5). The exact value and distribution of the magnetic field change, however, depended heavily on what was being spoken. Speaking the word "two" resulted in a maximum magnetic field change of approximately −5.6 Hz (0.044 ppm) in the inferior region of the brain. This corresponded to a 0.25 pixel shift in the image. Speaking the word "one" produced a slightly larger peak field change of approximately −11.1 Hz (0.087 ppm) in the inferior region. In addition, there was a positive change in the magnetic field of approximately 7.2 Hz (0.056 ppm) in the frontal lobe that was not observed while speaking the word "two." These signal changes correspond to a 0.5 pixel shift in the inferior region, and a 0.32 pixel shift in the frontal lobe.

DISCUSSION

The largest magnetic field change for both tasks occurred in the inferior region of the brain. This is to be expected, since it is closest to the site of the jaw and tongue movement occurring during these activities. On magnitude images, these magnetic field distortions appear as a warping, or shifting, of the image in the phase-encoding direction. For example, during a swallow, the brain stem and surrounding regions appear to shift and compress substantially during the swallow or speech. Since these signal changes are correlated with the motion, neurofunctional assessment during tasks involving speech or swallowing is difficult. These distortions could not be corrected by an image registration algorithm (23–25), since the image was warped by the

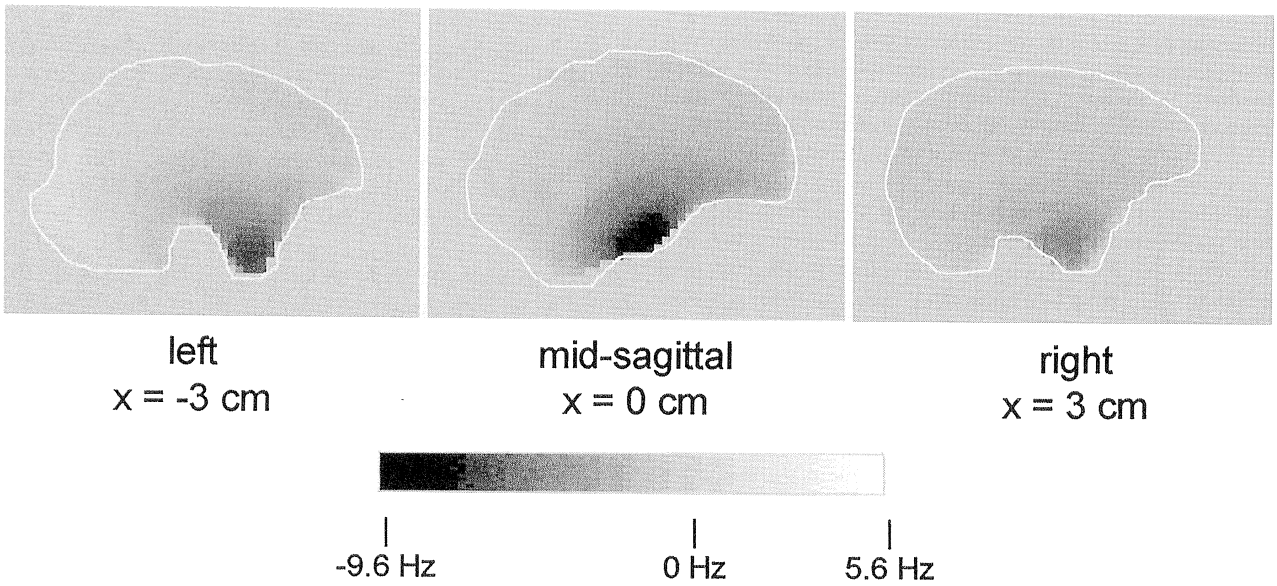

FIG. 4. Magnetic field changes during swallowing. Three sagittal slices are shown—a midsagittal slice and slices 3 cm to the left and to the right of the midline. The white tracing represents an outline of the brain as seen on the magnitude echo-planar images. Largest magnetic field changes occurred in the inferior region of the brain and decreased rapidly in the superior and lateral directions as the distance to the source of the motion, the jaw and the tongue, is increased.

magnetic field perturbation, rather than simply rotated and translated.

Speaking the words "one" and "two" involves different movements of the tongue and jaw, explaining the observed difference in the associated magnetic field distortion. Speaking the word "one" involves significant movement of both the tongue and jaw, and an opening of the palate. The word "two," in contrast, begins with a closed palate and involves no significant jaw movement and only slight tongue movement (26). The greater motion of the tongue in speaking the word "one" can thus lead to a larger distortion in the magnetic field in the inferior region of the brain, whereas the motion of the jaw, which is minimal in speaking the word "two," can induce further changes in the magnetic field in the anterior regions of the brain.

A potential difficulty in obtaining a true measure of magnetic field changes from phase images is that motion of the subjects head (intra-FOV motion) also influences the phase. This phase change comes primarily from two sources—motion of the subject's head through an externally inhomogenous magnetic field, and changes in the magnetic field perturbation produced by the susceptibility of the human head. Thus, a shift in the phase reflects either true changes in the magnetic field or intra-FOV motion. This error in the magnetic field measurement is eliminated in this study by unwarping the magnetic field maps, as illustrated in Fig. 3. The process of unwarping the magnetic field maps corrects for any phase changes caused by motion of the subject's head through an externally inhomogenous magnetic field. The only change in the corrected magnetic field map resulting from intra-FOV motion comes from actual perturbations in the magnetic field produced by rotation of the head. The latter effect is reduced by acquiring the two images used to create the magnetic field map with a temporal separation of only 100 ms.

The dynamic magnetic field mapping technique presented here compares the difference between an image acquired during the free induction decay (FID) and an image acquired during the latter half of the spin echo, shifted to a longer effective echo time ($TE_{GE} + \Delta TE$). An alternative, suggested by one of the referees, is to shift the second image to a shorter effective echo time ($TE_{GE} - \Delta TE$). This would produce the same measurement of the magnetic field with a reduction in interimage time, a

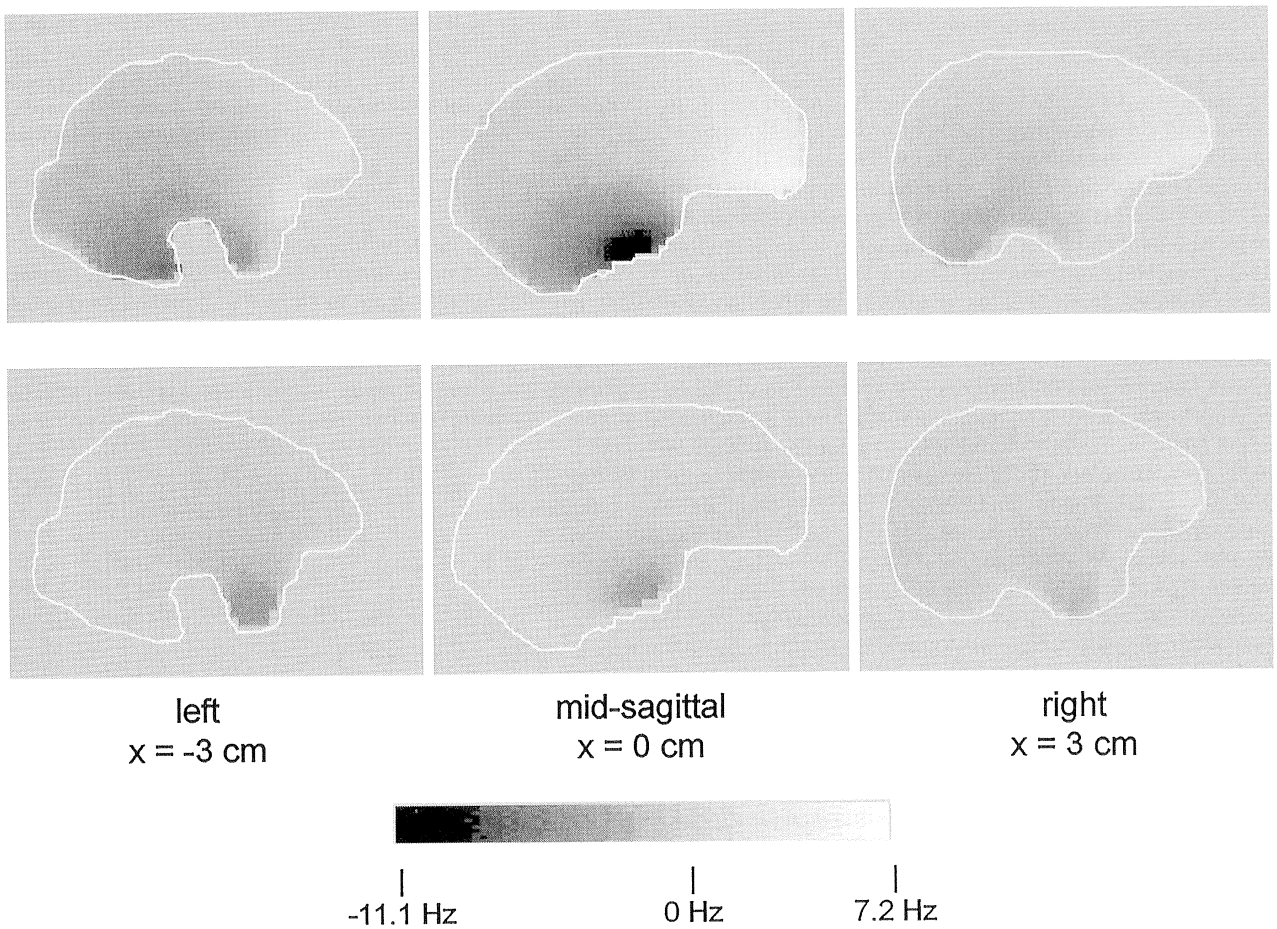

FIG. 5. Top: magnetic field changes while the subject spoke the word "one." Bottom: magnetic field changes while the subject spoke the word "two." Three sagittal slices are shown—a midsagittal slice and slices 3 cm to the left and to the right of the midline. The white tracing represents an outline of the brain as seen on the magnitude echo-planar images. In both cases, the largest magnetic field changes occur in the inferior region of the brain, closest to the site of most of the jaw and tongue motion. Speaking the word "one" produces slightly larger magnetic field changes in the inferior region and additional changes in the magnetic field in the frontal region of the brain.

reduction in TR, and a somewhat greater signal-to-noise ratio.

An important distinction between magnetic field-induced signal changes and BOLD signal changes is that the signal intensity changes caused by the magnetic field occur nearly instantaneously, whereas the BOLD signal changes typically lag 5–7 s due to the slower hemodynamic response (27). Therefore, signal intensity changes that occur immediately after the onset or cessation of the stimulus are a good indication of an artifact. This, however, cannot be used as the sole criterion for distinguishing pixels corrupted by motion or magnetic field distortions, since slower movements will lead to slower signal intensity changes (13). These artifactual signal changes can still be present after a correlation analysis, because the correlation is only 0 if the time series of the motion is orthogonal to the signal intensity time series from the slower hemodynamic response to the stimulus. Motions, especially those associated with speaking, and hence the temporal variations in the magnetic field, can be quite complicated. Thus, in general, the correlation between the motion or magnetic field-induced signal changes and a reference function representing the hemodynamic response to the stimulus will not be 0, and the artifact is not eliminated.

CONCLUSION

As demonstrated here, considerable changes in the magnetic field do occur as a result of either swallowing or speaking. These changes lead to distortions in the image that can complicate fMRI experiments, especially those in which the tasks involve speaking or swallowing. In tasks not explicitly involving speaking or swallowing, field changes from these motions as well as from respiratory motion, lead to signal fluctuations that increase the noise in task activation studies (28, 29). Since the magnetic field perturbation warps the image, the artifact cannot be corrected using conventional rigid body image registration algorithms. The detection of these artifactual signal changes from solely the magnitude images is often quite difficult, since the motions involved can be quite complex. The dynamic mapping of the magnetic field opens an avenue by which these magnetic field distortion-induced signal changes can be detected and eventually corrected by unwarping the image in correspondence to the spatial variation of the magnetic field, as in Eqs. [1] and [2]. This is an important step in the eventual elimination of artifacts resulting from activities during the functional imaging scan such as swallowing and speaking.

REFERENCES

1. P. A. Bandettini, E. C. Wong, R. S. Hinks, R. S. Tikofsky, J. S. Hyde, Time course EPI of human brain function during task activation. *Magn. Reson. Med.* **25,** 390–397 (1992).
2. K. K. Kwong, J. W. Belliveau, D. A. Chester, I. E. Goldberg, R. M. Weisskoff, B. P. Poncelet, D. N. Kennedy, B. E. Hoppel, M. S. Cohen, R. Turner, H-M. Cheng, T. J. Brady, B. R. Rosen, Dynamic magnetic resonance imaging of human brain activity during primary sensory stimulation. *Proc. Natl. Acad. Sci. USA* **89,** 5675–5679 (1992).
3. S. Ogawa, D. W. Tank, R. Menon, J. M. Ellerman, S.-G. Kim, H. Merkle, K. Ugurbil, Intrinsic signal changes accompanying sensory stimulation: functional brain mapping with magnetic resonance imaging. *Proc. Natl. Acad. Sci. USA* **89,** 5951–5955 (1992).
4. J. Frahm, H. Bruhn, K.-D. Merboldt, W. Hanicke, D. Math, Dynamic MR imaging of human brain oxygenation during rest and photic stimulation. *J. Magn. Reson. Imaging* **2,** 501–505 (1992).
5. M. Kern, R. Shaker, I. Lang, A. Jesmanowicz, J. S. Hyde, R. C. Anderdorfer, Cerebral cortical activity pattern recorded by functional magnetic-resonance imaging technique during a swallow related motor task in humans. *Gastroenterology* **108,** A627 (1995) [Abstract].
6. I. Lang, R. Layman, V. Haughton, L. Estkowski, E. Wong, J. S. Hyde, W. Hogan, R. Shaker, Detection of cerebral activity during swallowing by functional magnetic resonance imaging (MRI). *Gastroenterology* **106,** A529 (1994) [Abstract].
7. R. Shaker, M. Kern, R. C. Arndorfer, I. Lang, A. Jesmanowicz, J. S. Hyde, Identification and characterization of the cerebral cortical activity pattern during esophageal balloon distention by functional magnetic resonance imaging technique. *Gastroenterology* **108,** A634 (1995) [Abstract].
8. K. Mosier, W. C. Liu, J. Maldjian, Functional MRI of swallowing, *in* "Proc. ISMRM, 5th Scientific Meeting, Vancouver, 1997," p. 457.
9. J. R. Binder, Functional magnetic resonance imaging of the language cortex. *Int. J. Imaging Syst. Technol.* **6,** 280–288 (1995).
10. A. C. Guyton, "Textbook of Medical Physiology," Saunders, Philadelphia, 1986.
11. J. V. Hajnal, R. Myers, A. Oatridge, J. E. Schwieso, I. R. Young, G. M. Bydder, Artifacts due to stimulus correlated motion in functional imaging of the brain. *Magn. Reson. Med.* **31,** 283–291 (1994).
12. F. Z. Yetkin, V. M. Haughton, R. W. Cox, J. S. Hyde, R. M. Birn, E. C. Wong, R. Prost, Effect of motion outside the field of view on functional MR. *AJNR* **17,** 1005–1009 (1996).
13. R. M. Birn, F. Z. Yetkin, J. S. Hyde, Artifact in FMRI caused by motion outside the FOV, *in* "Proc., ISMRM, 4th Annual Meeting, New York, 1996," p. 1770.
14. F. Farzaneh, S. J. Riederer, N. J. Pelc, Analysis of T2 limitations and off-resonance effects in spatial resolution and artifacts in echo-planar imaging. *Magn. Reson. Med.* **14,** 123–139 (1990).
15. E. A. Schneider, G. Glover, Rapid in vivo proton shimming. *Magn. Reson. Med.* **18,** 335–347 (1991).
16. P. A. Bandettini, A. Jesmanowicz, R. M. Birn, J. Van Kylen, J. S. Hyde, Combined gradient-echo and asymmetric spin echo (GREASE): functional MRI comparison and uses, *in* "Proc., ISMRM, 5th Scientific Meeting, Vancouver, 1997," p. 1639.
17. W. J. Dodds, J. A. Logemann, E. T. Stewart, Radiological assessment of abnormal oral and pharyngeal phases of swallowing. *AJR* **154,** 965–974 (1990).
18. J. A. Logemann, "Evaluation and Treatment of Swallowing Disorders," College-Hill Press, Boston, 1983.
19. E. C. Wong, P. A. Bandettini, J. S. Hyde, Echo-planar imaging of the human brain using a three axis local gradient coil, *in* "Proc., SMRM, 11th Annual Meeting, Berlin, 1992," p. 105.
20. M. Hedley, D. Rosenfeld, A new two-dimensional phase unwrapping algorithm for MRI images. *Magn. Reson. Med.* **24,** 177–181 (1992).
21. P. Jezzard, R. S. Balaban, Correction for geometric distortion in echo planar images from B_0 inhomogeneities. *Magn. Reson. Med.* **34,** 65–73 (1995).
22. R. M. Weisskoff, T. L. Davis, Correcting gross distortion on echo planar images, *in* "Proc., SMRM, 11th Annual Scientific Meeting, Berlin, 1992," p. 4515.
23. K. J. Friston, J. Ashburner, C. D. Frith, J.-B. Poline, J. D. Heather, R. S. J. Frackowiak, Spatial registration and normalization of images. *Hum. Brain Mapping* **3,** 165–189 (1995).
24. J. V. Hajnal, N. Saeed, E. J. Soar, A. Oatridge, I. R. Young, G. M. Bydder, A registration and interpolation procedure for subvoxel matching of serially acquired MR images. *J. Comput. Assist. Tomogr.* **19,** 289–296 (1995).
25. R. P. Woods, J. C. Mazziotta, S. R. Cherry, MRI-PET registration with automated algorithm. *J. Comput. Assist. Tomogr.* **17,** 536–546 (1993).
26. V. C. Tartter, "Language Processes," Holt, Rinehart, Winston, New York, 1986.
27. E. A. DeYoe, P. A. Bandettini, J. Neitz, D. Miller, P. Winans, Functional magnetic resonance imaging (FMRI) of the human brain. *J. Neurosci. Methods* **54,** 171–187 (1994).
28. X. Hu, T. H. Le, T. Parrish, P. Erhard, Retrospective estimation and correction of physiological fluctuation in functional MRI. *Magn. Reson. Med.* **34,** 201–212 (1995).
29. B. Biswal, E. A. DeYoe, J. S. Hyde, Reduction of fluctuations in fMRI using digital filters. *Magn. Reson. Med.* **35,** 107–113 (1996).