

NEUROIMAGING

(...at the NIH)

Peter A. Bandettini, Ph.D.

bandettini@nih.gov

Functional MRI Facility

Unit on Functional Imaging Methods

Laboratory of Brain and Cognition

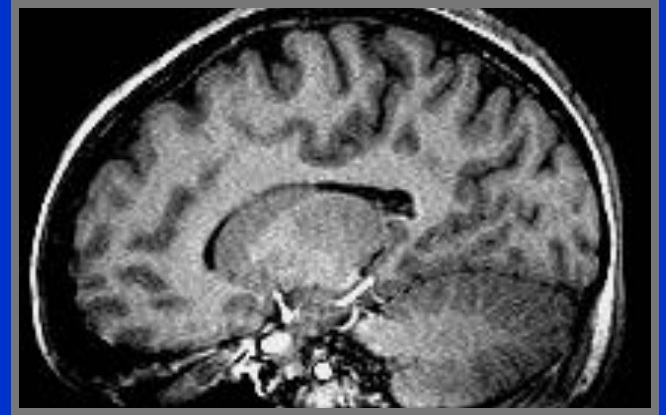


Two Types of Neuroimaging

- Structural/Anatomical Imaging
- Functional Imaging

Structural Brain Imaging

- Reveals the anatomy of the brain and the physical structure of brain pathology.



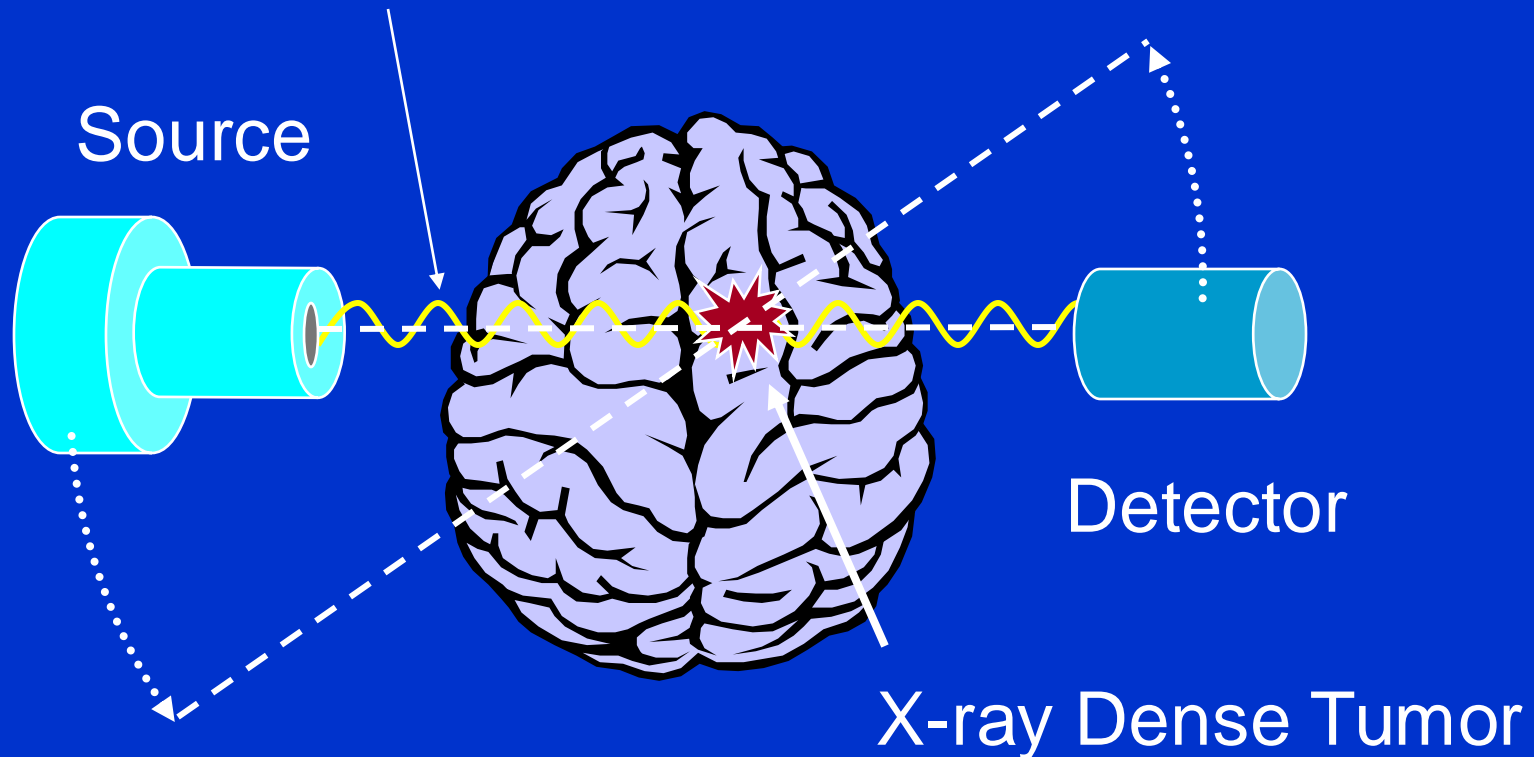
- Primarily associated with Computerized Axial Tomography (CAT or CT) and Magnetic Resonance Imaging (MRI).

- **Structural/Anatomical Imaging**
 - X-ray
 - Computerized Tomography (CT)
 - Magnetic Resonance Imaging (MRI)
 - Angiography
 - Venography
 - Perfusion
 - Diffusion Tensor Imaging

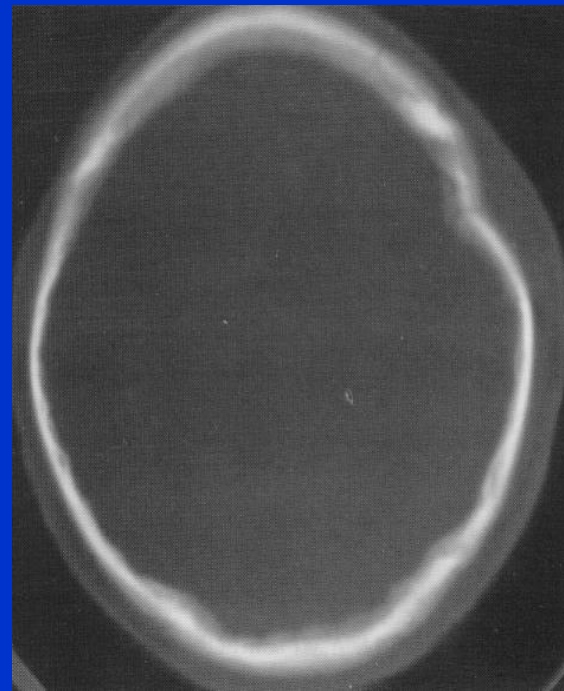
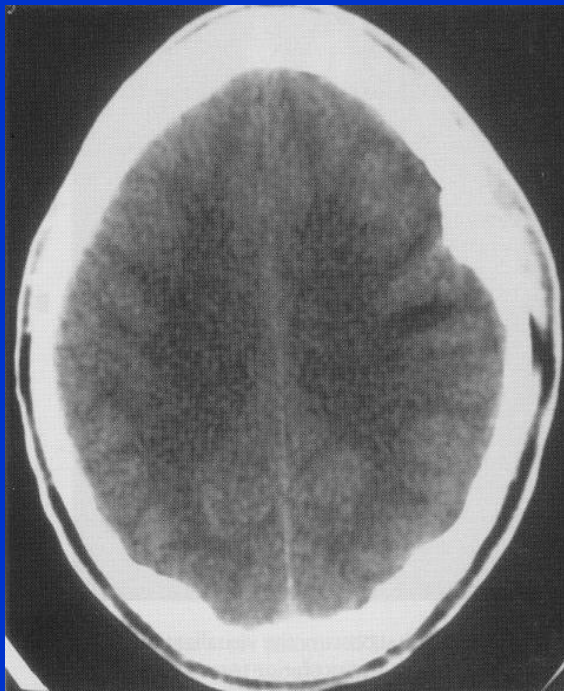Computerized Tomography (CT)

Creation of images in slices or sections.

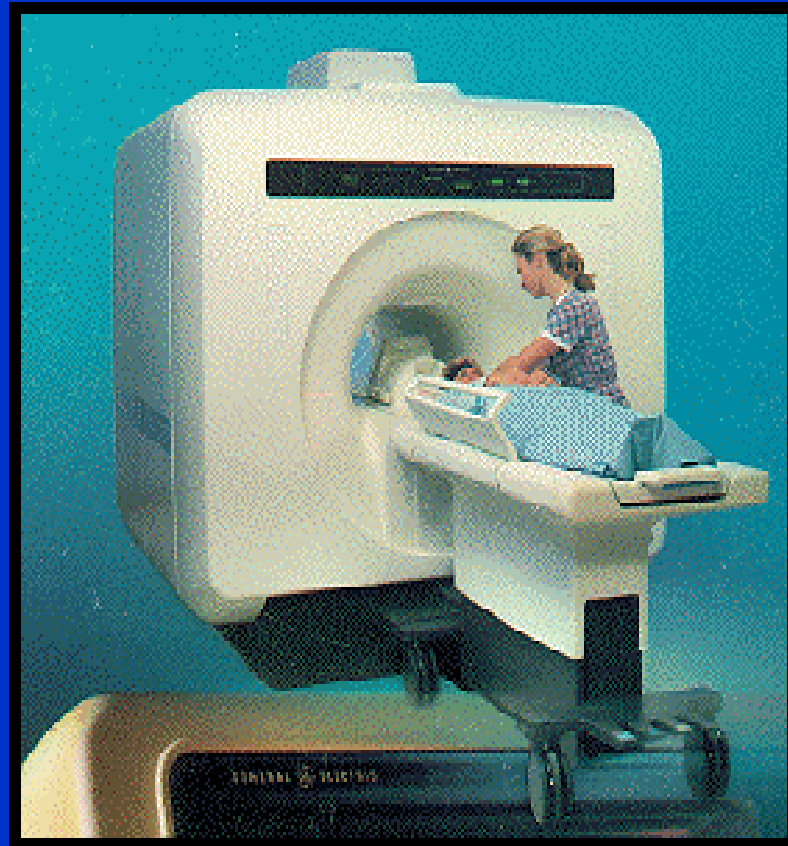
Narrow X-ray beam



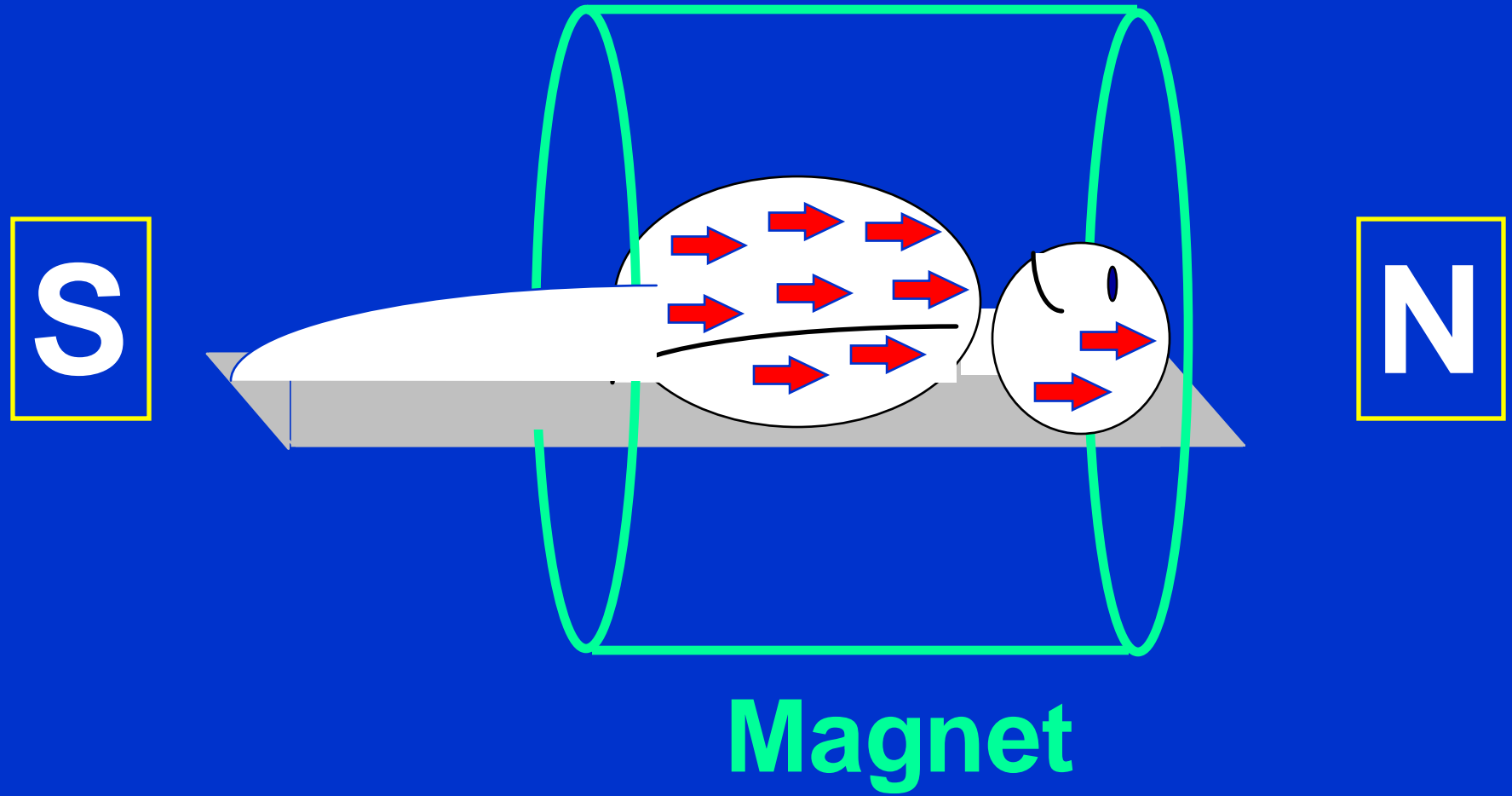
CT Images



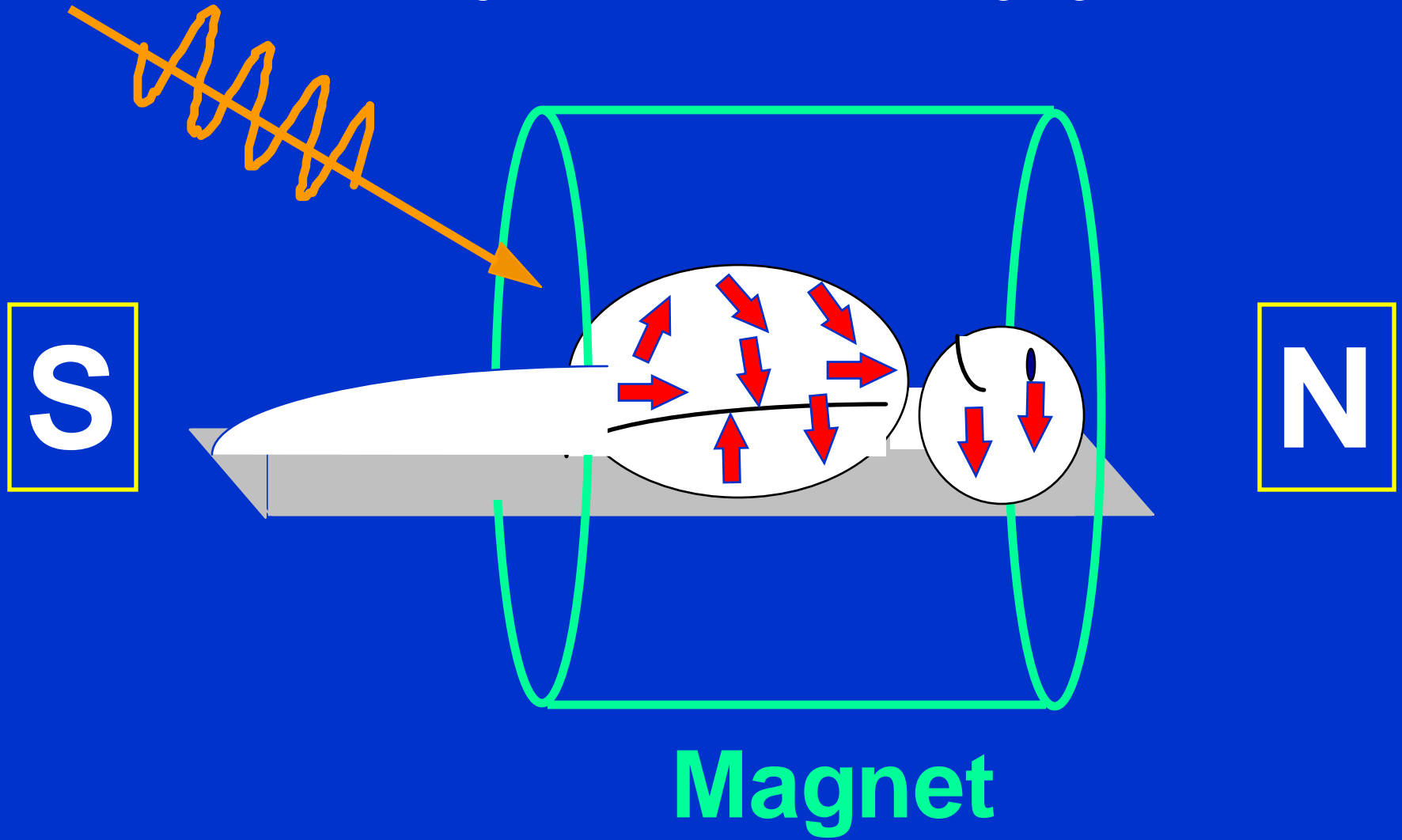
Magnetic Resonance Imaging



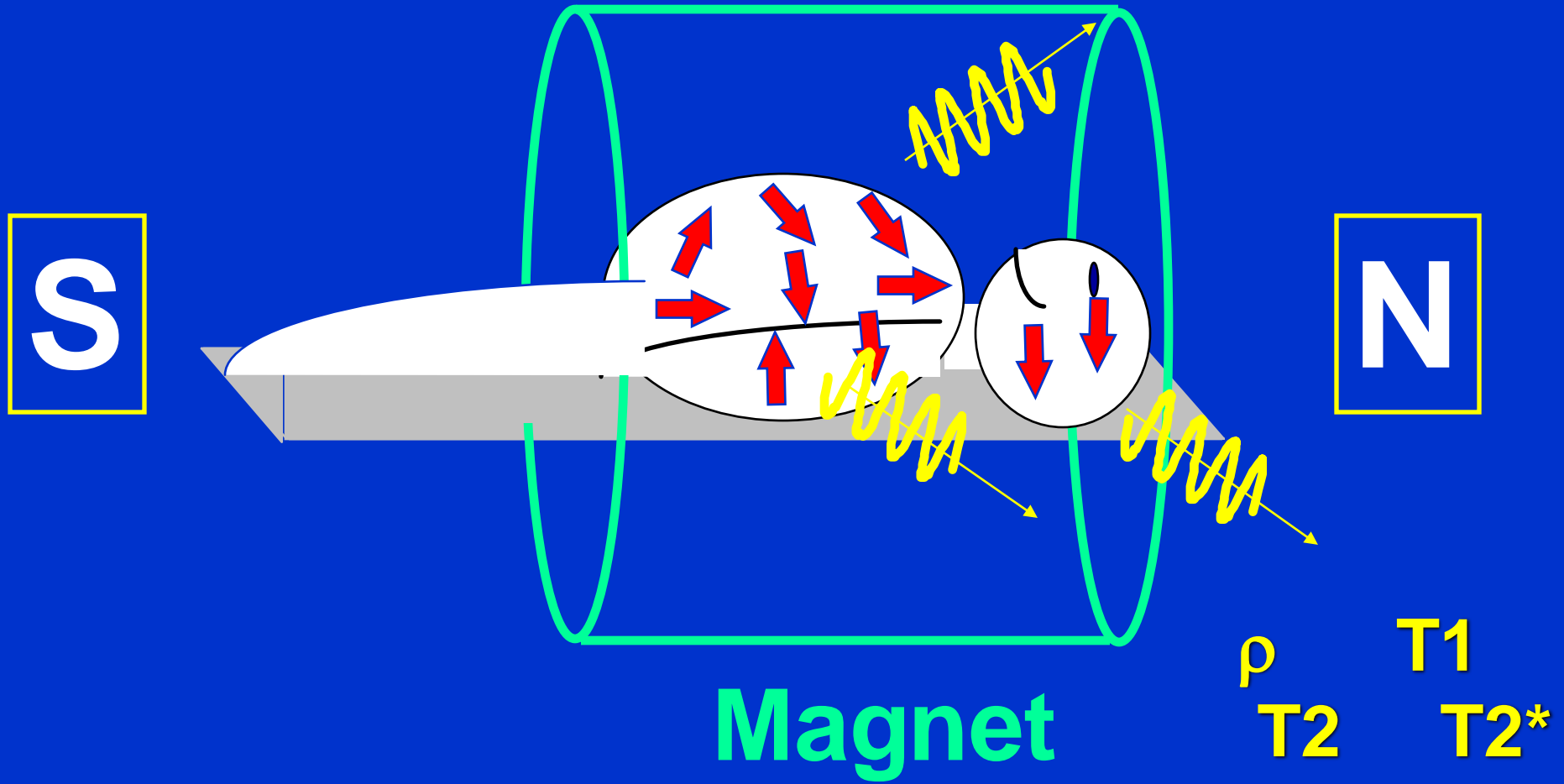
Magnetic Resonance Imaging



Magnetic Resonance Imaging

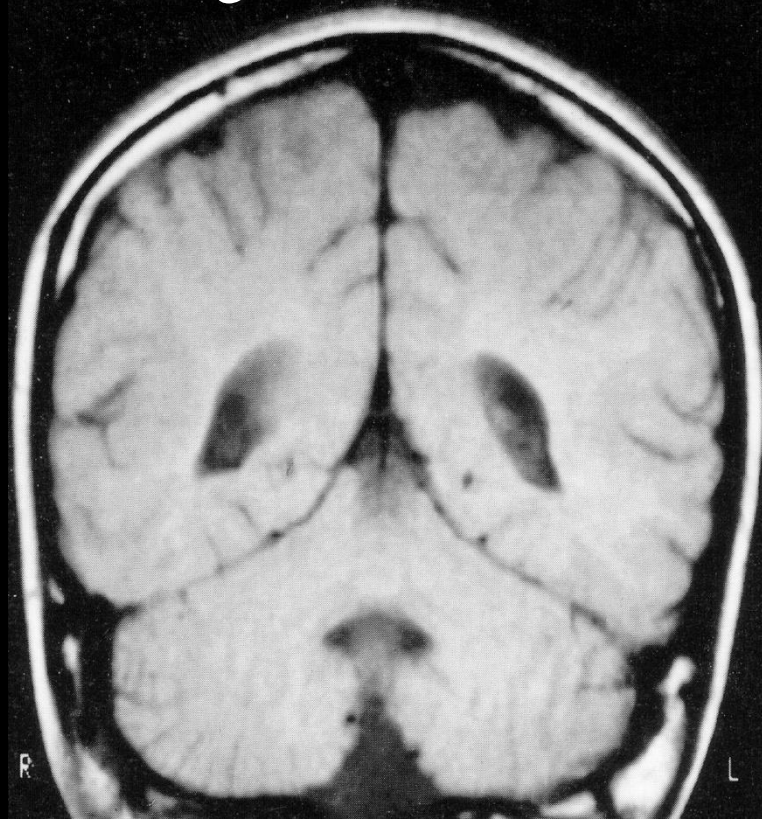


Magnetic Resonance Imaging

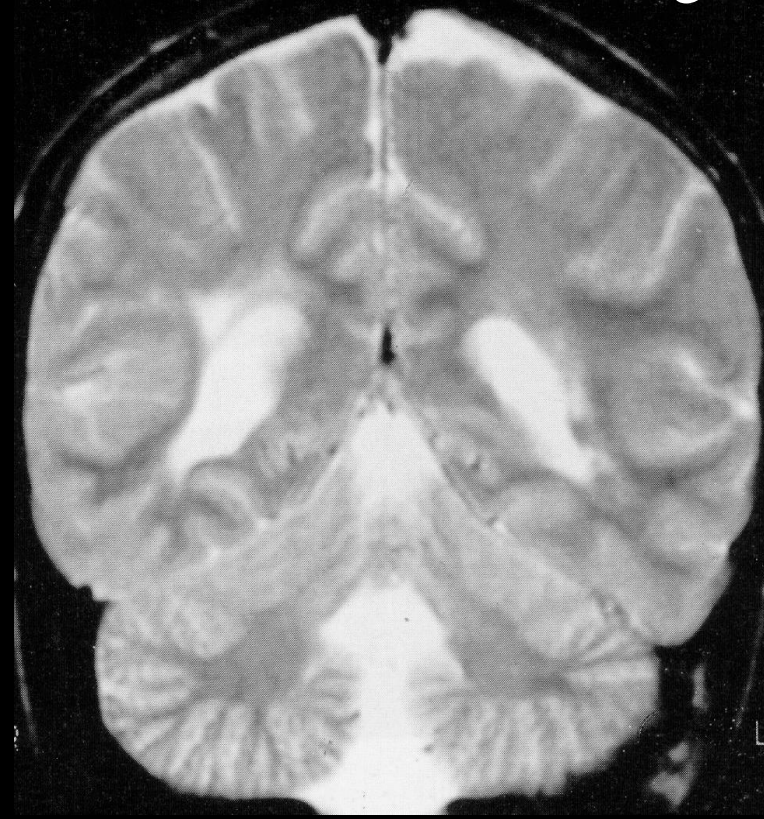


MRI Images with Different Contrast Weighting

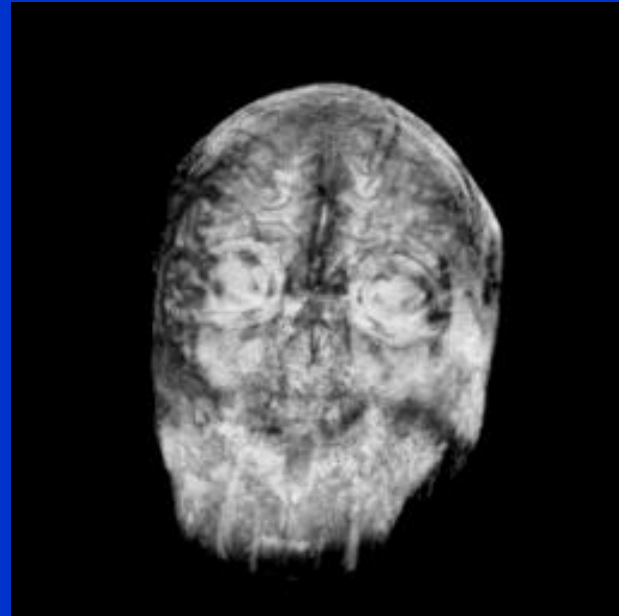
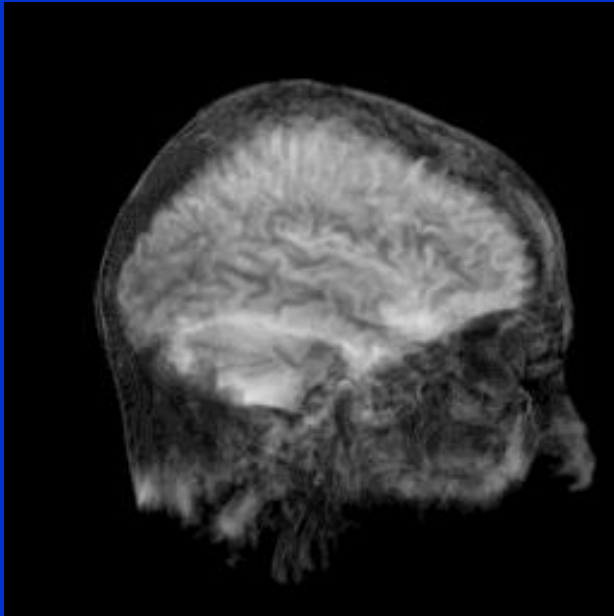
T1 Weighted



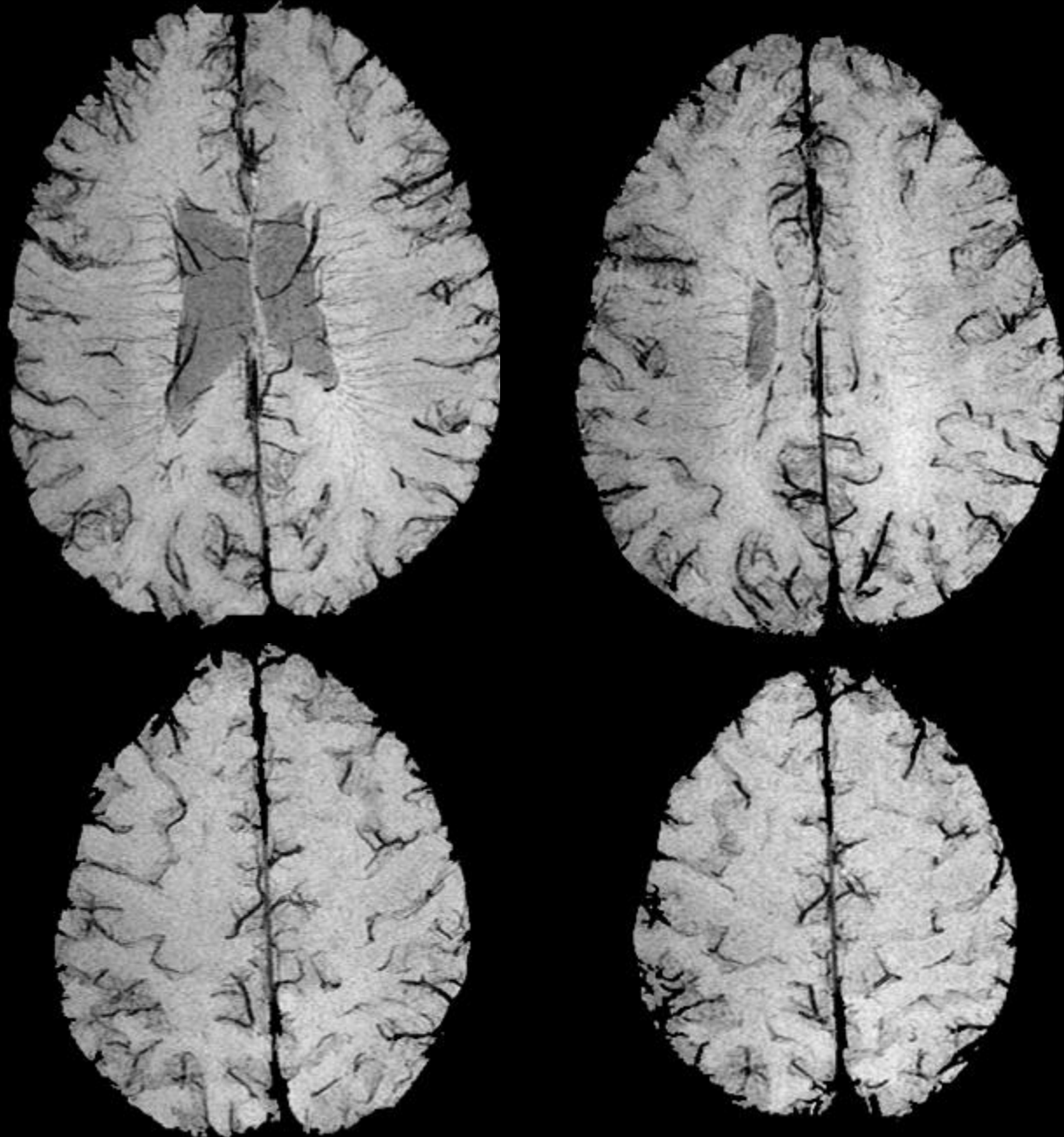
T2 Weighted



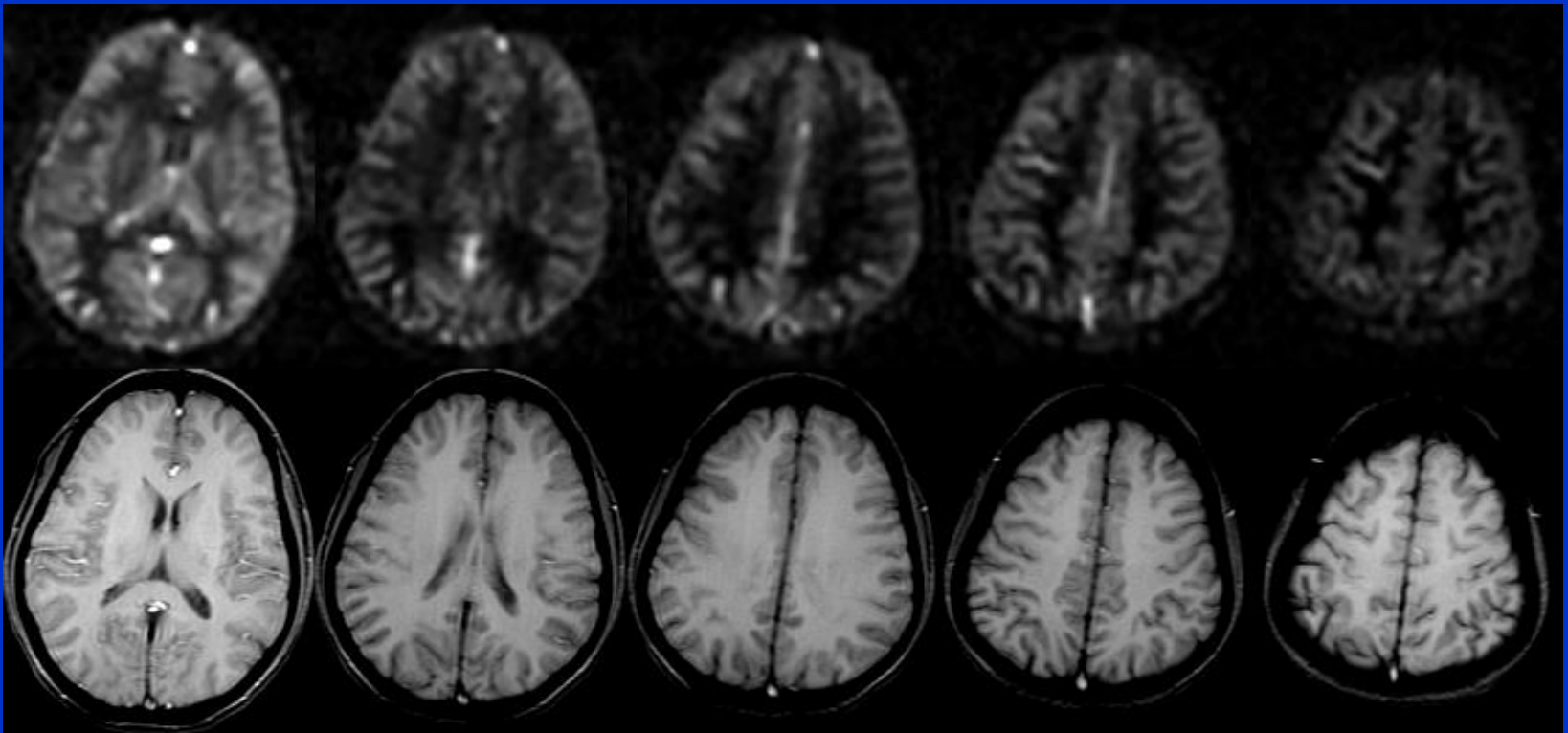
3D Rendering



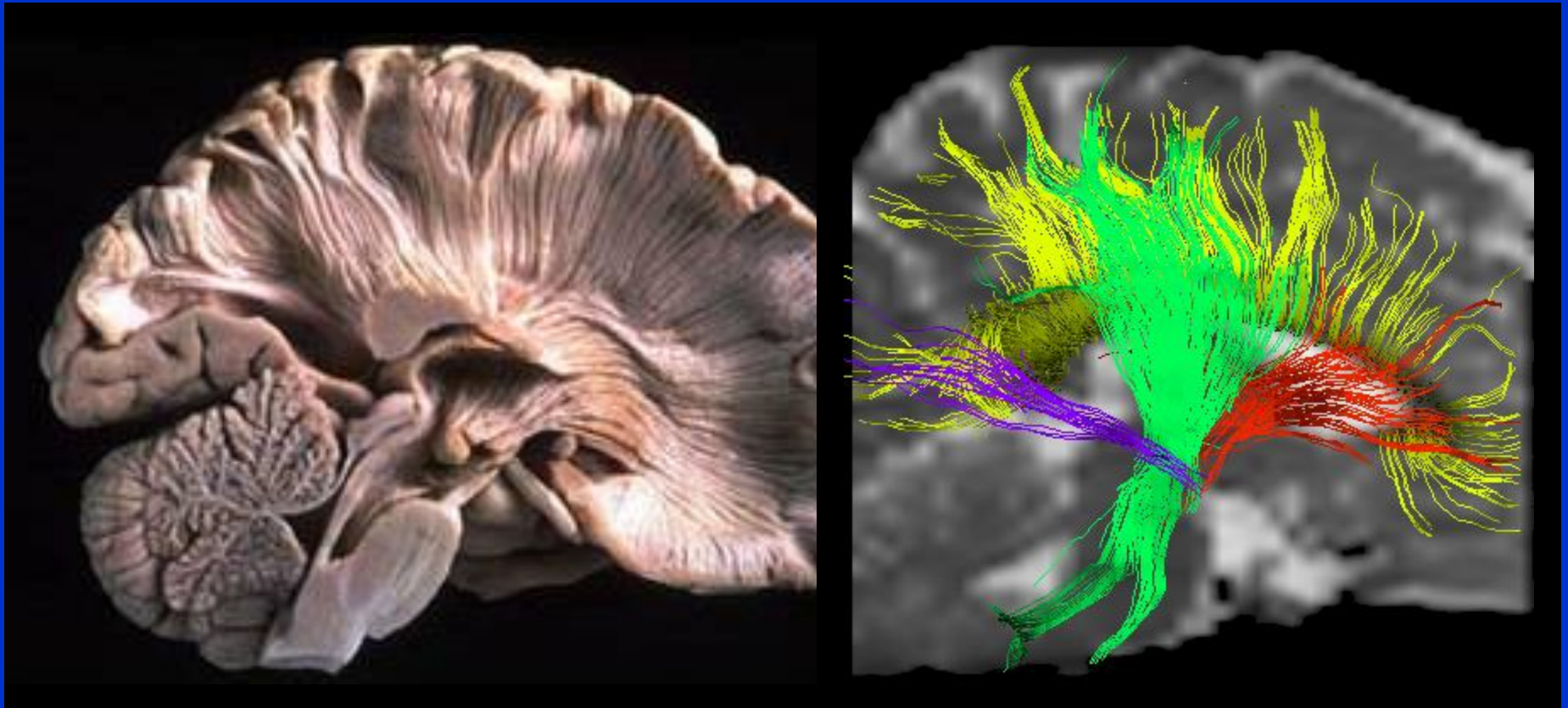
Venograms (3T)



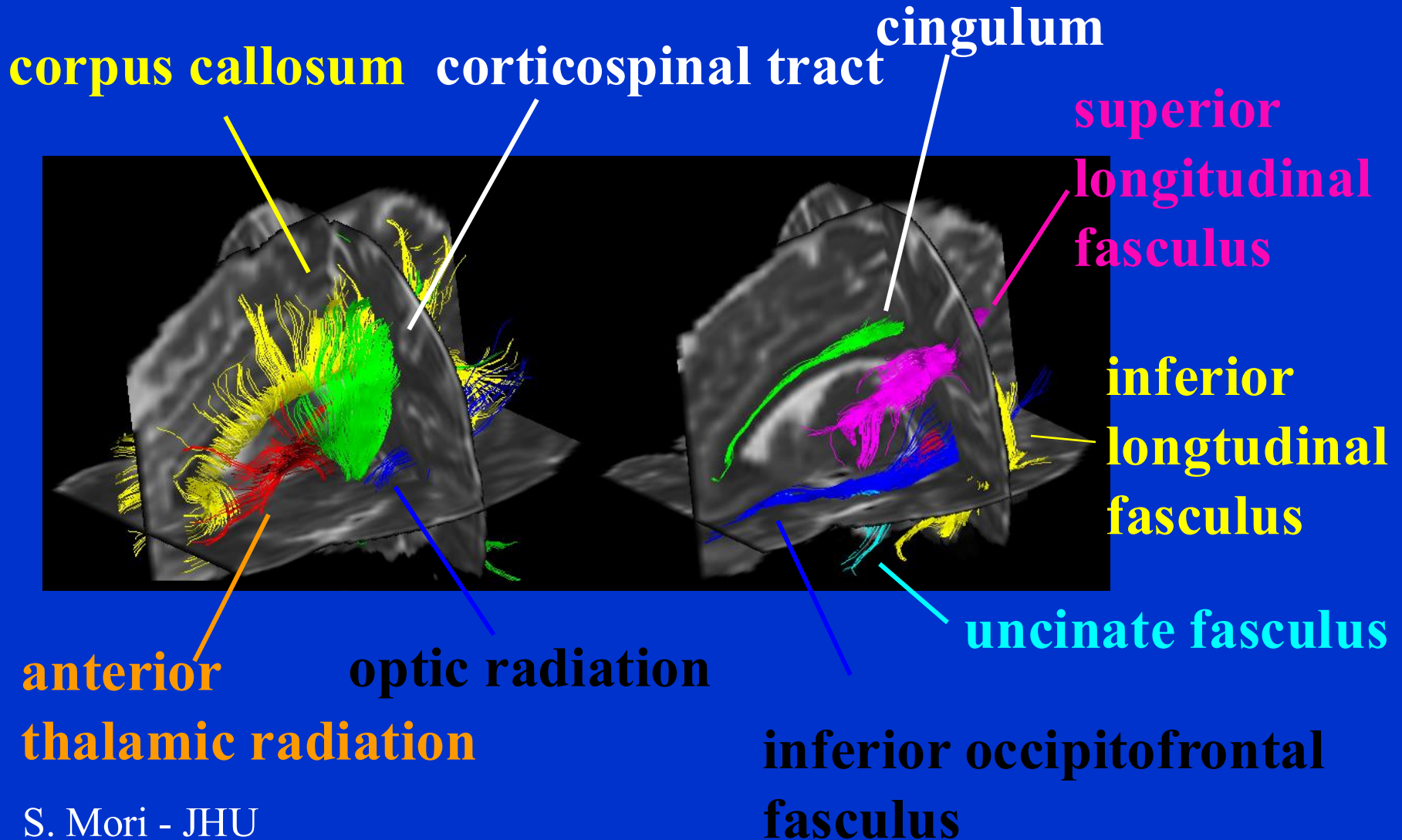
Perfusion Imaging with MRI



Diffusion Tensor Imaging

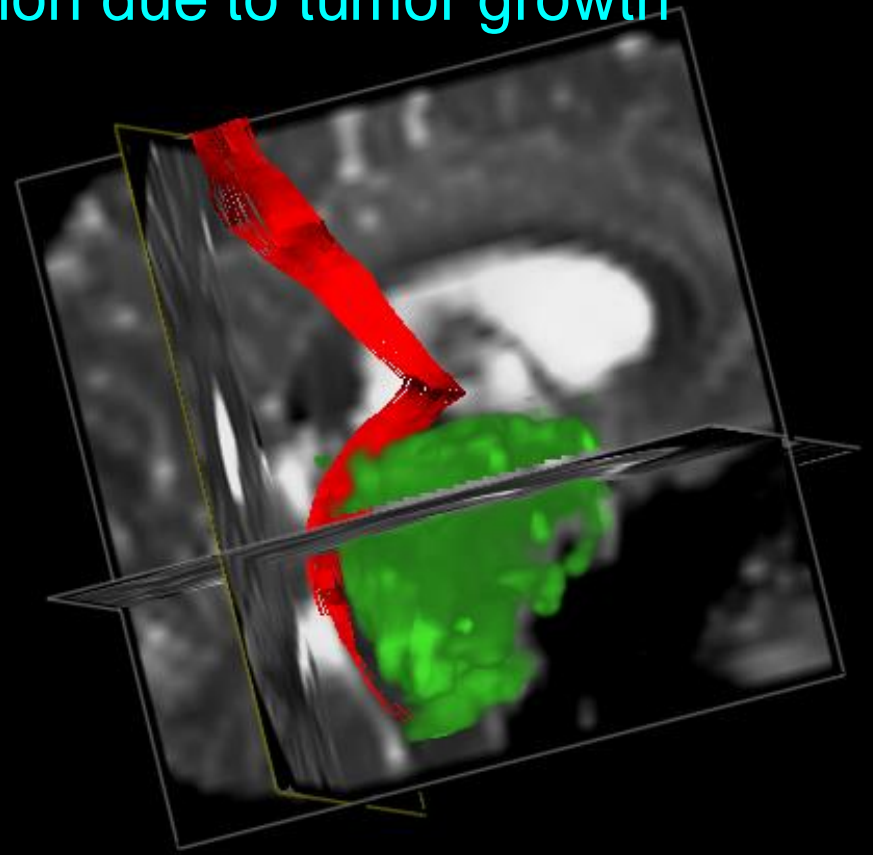
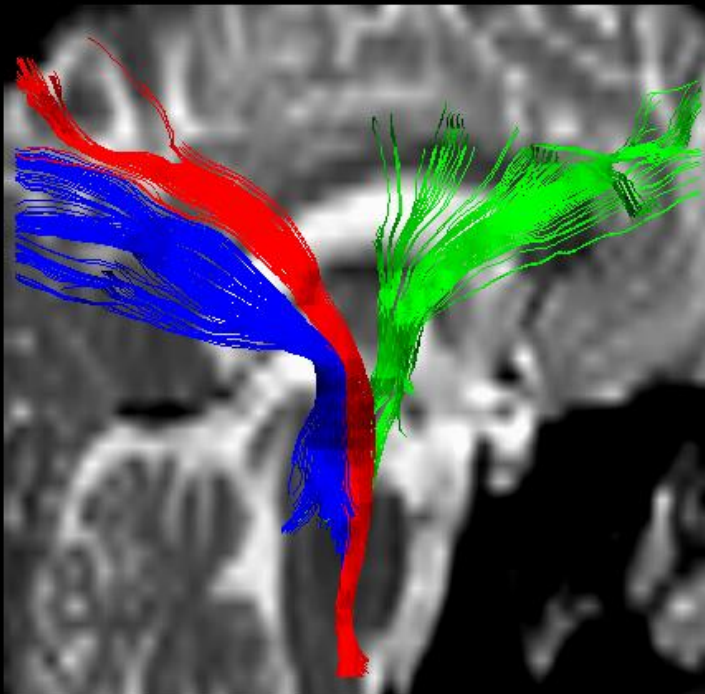


Diffusion Tensor Imaging



Anatomical guidance with DTI:

Example: Anatomical deformation due to tumor growth



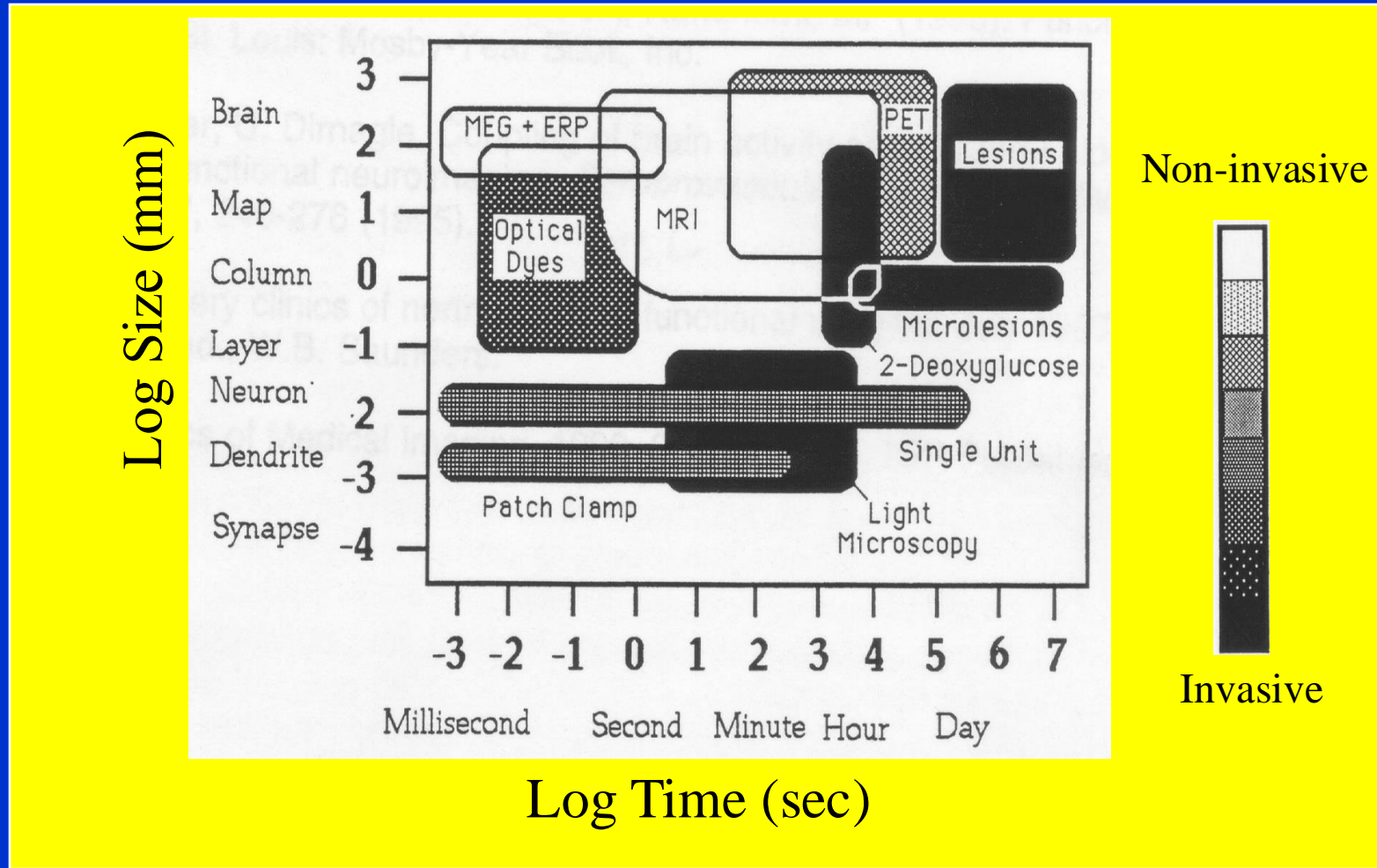
Functional Imaging

- Unlike structural imaging, functional imaging provides pictures of brain physiology or chemistry.
- By targeting factors that are related to brain activity (eg. blood flow and oxygenation), images of brain activation can be obtained.
- Functional imaging has been used for pre-surgical mapping of function and, eventually, may replace or augment more traditional tests.
- Functional imaging is now a major new research paradigm in neuroscience.

•Functional Imaging

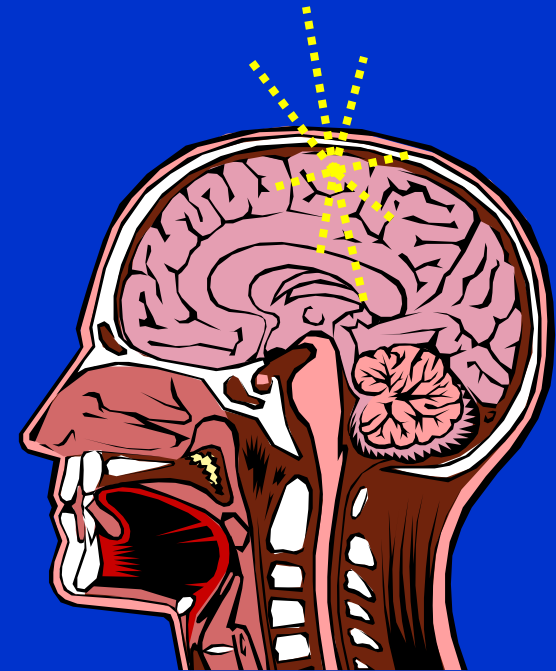
- Xenon Computerized Tomography (Xe CT)
- Positron Emission Tomography (PET)
- Single Photon Computed Tomography (SPECT)
- Functional MRI (fMRI)
- Electroencephalography (EEG)
- Magnetoencephalography (MEG)
- Transcranial Magnetic Stimulation (TMS)

Functional Neuroimaging Techniques

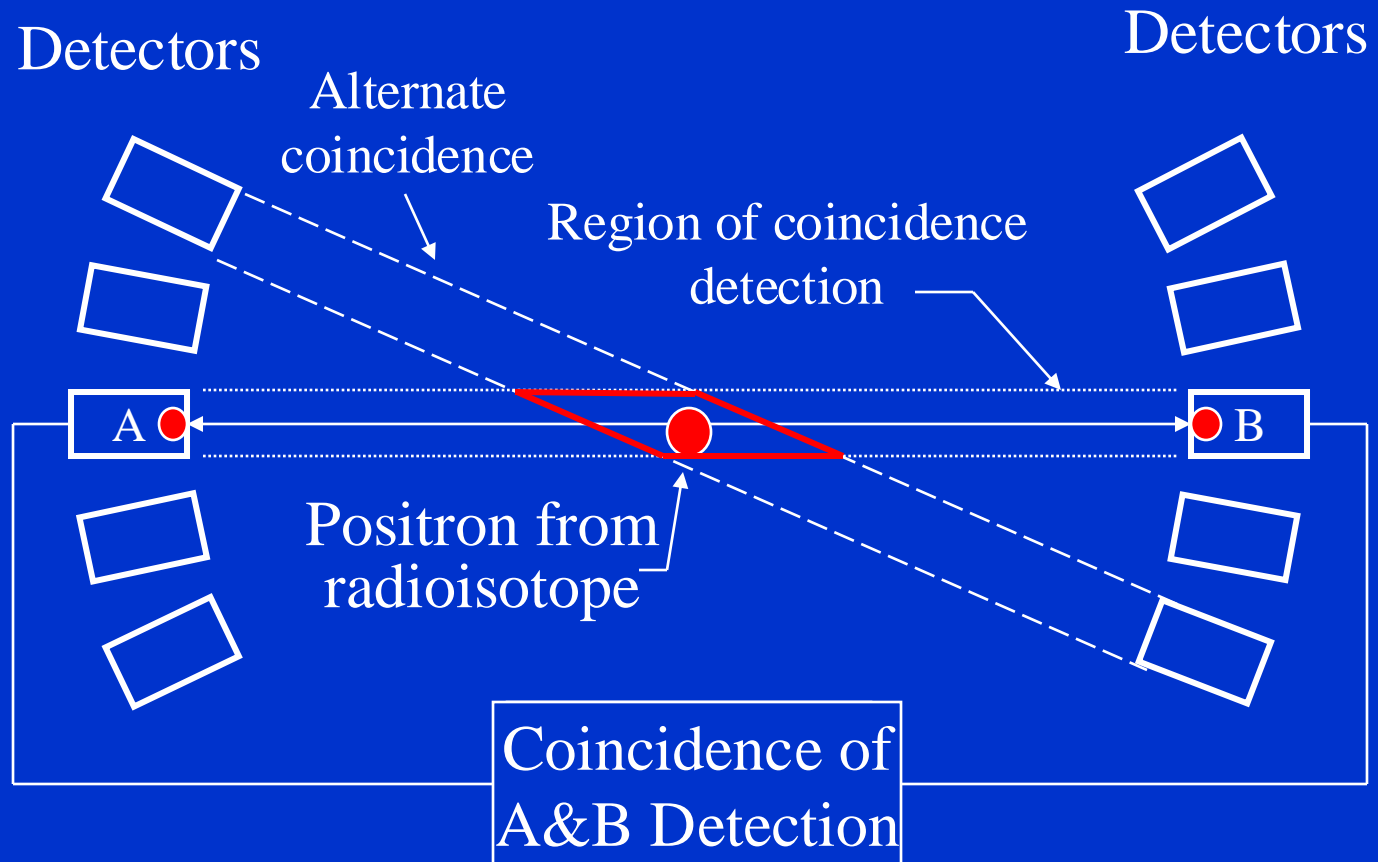


Positron Emission Tomography (PET)

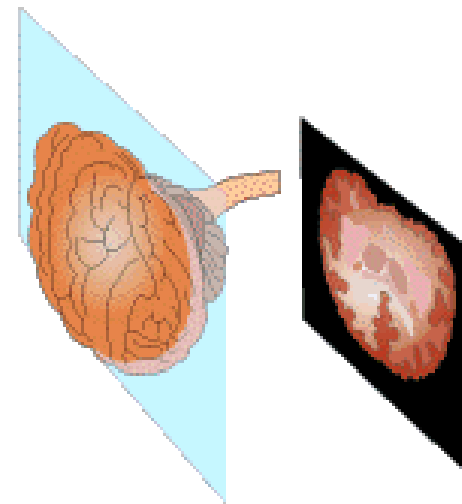
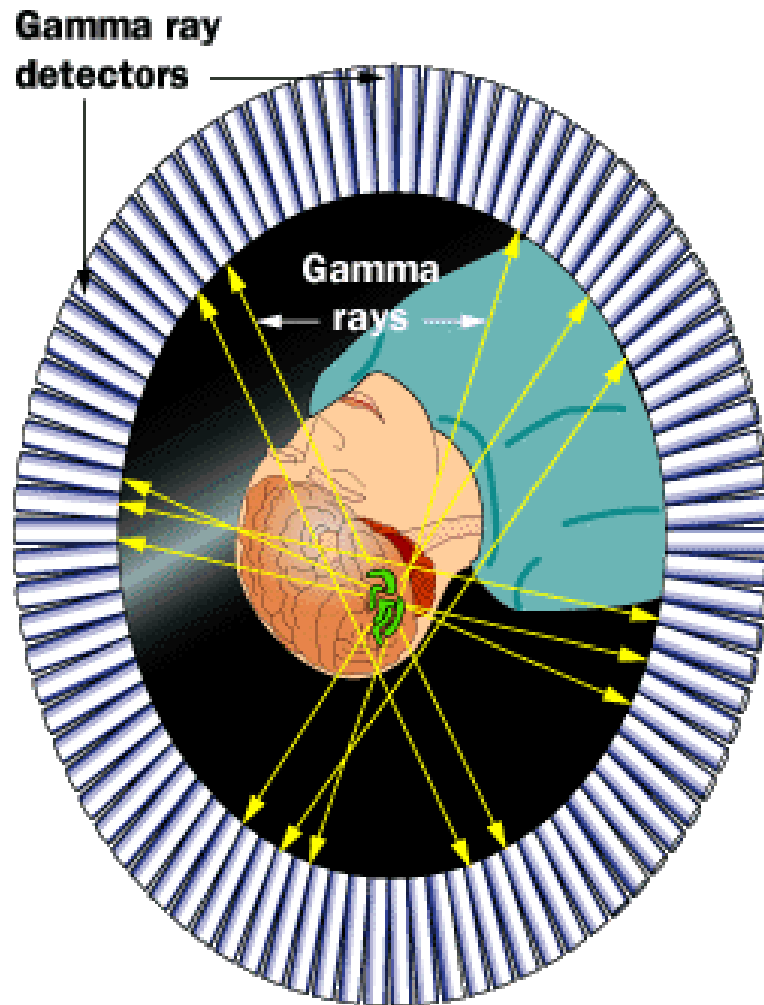
- Positron emission tomography (PET) is a technique for studying functional processes *in vivo* by measuring the concentrations of positron-emitting radioisotopes within the subject.
- PET is primarily used to study biochemical and physiological processes within living organs with 3-dimensional spatial resolution.

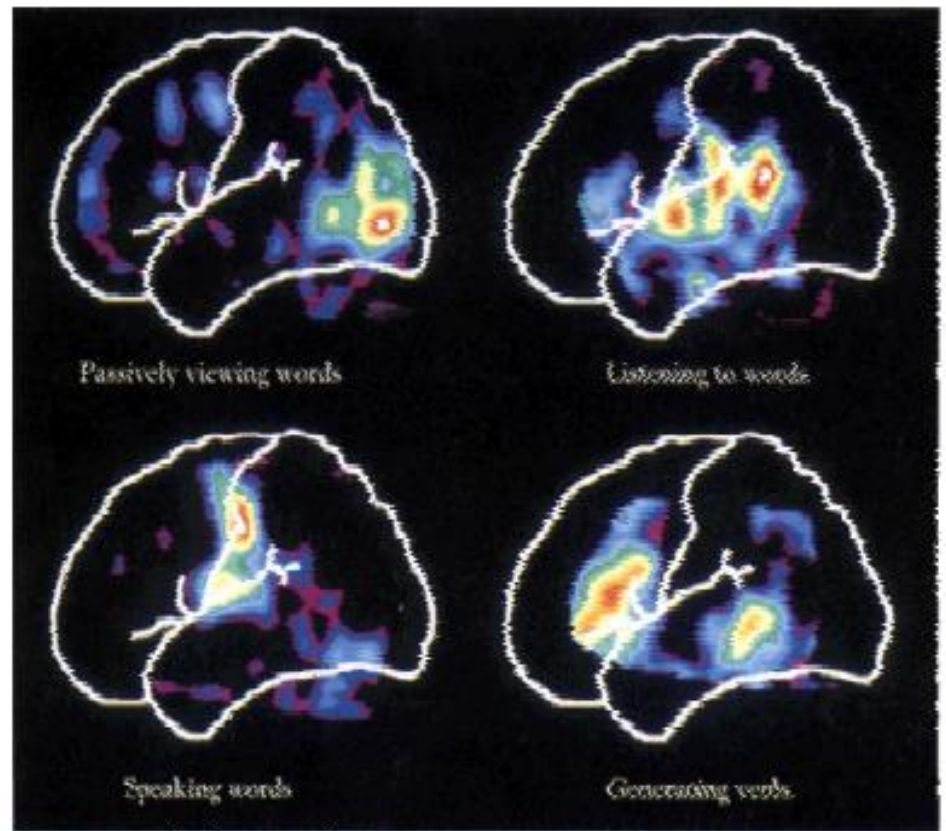
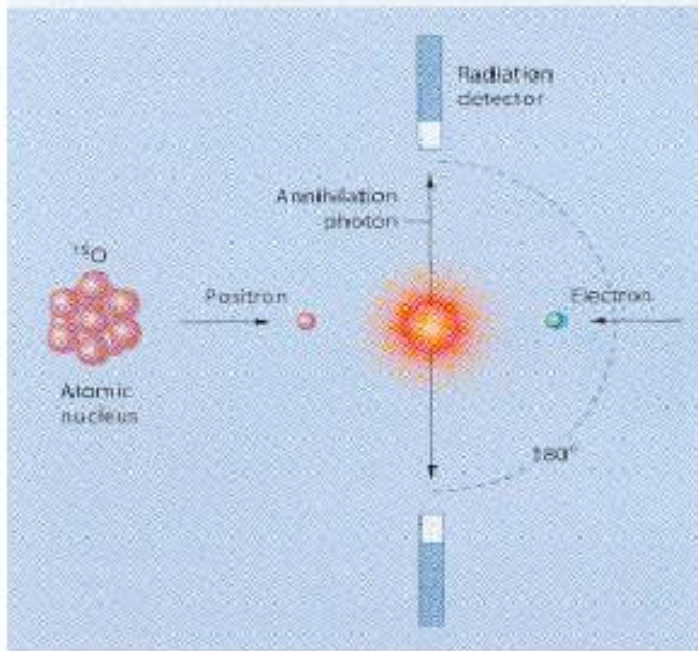
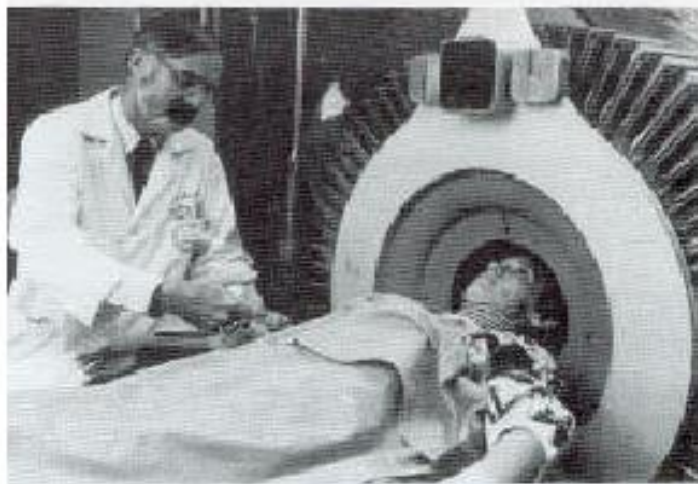

PET mechanism



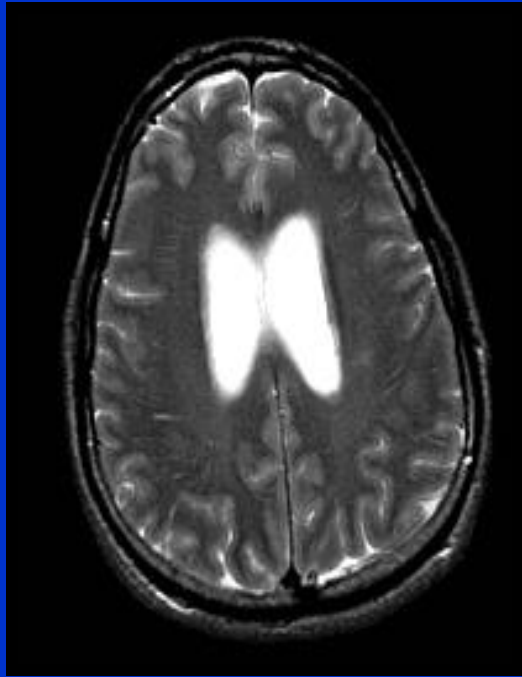
Positron Emission Tomography



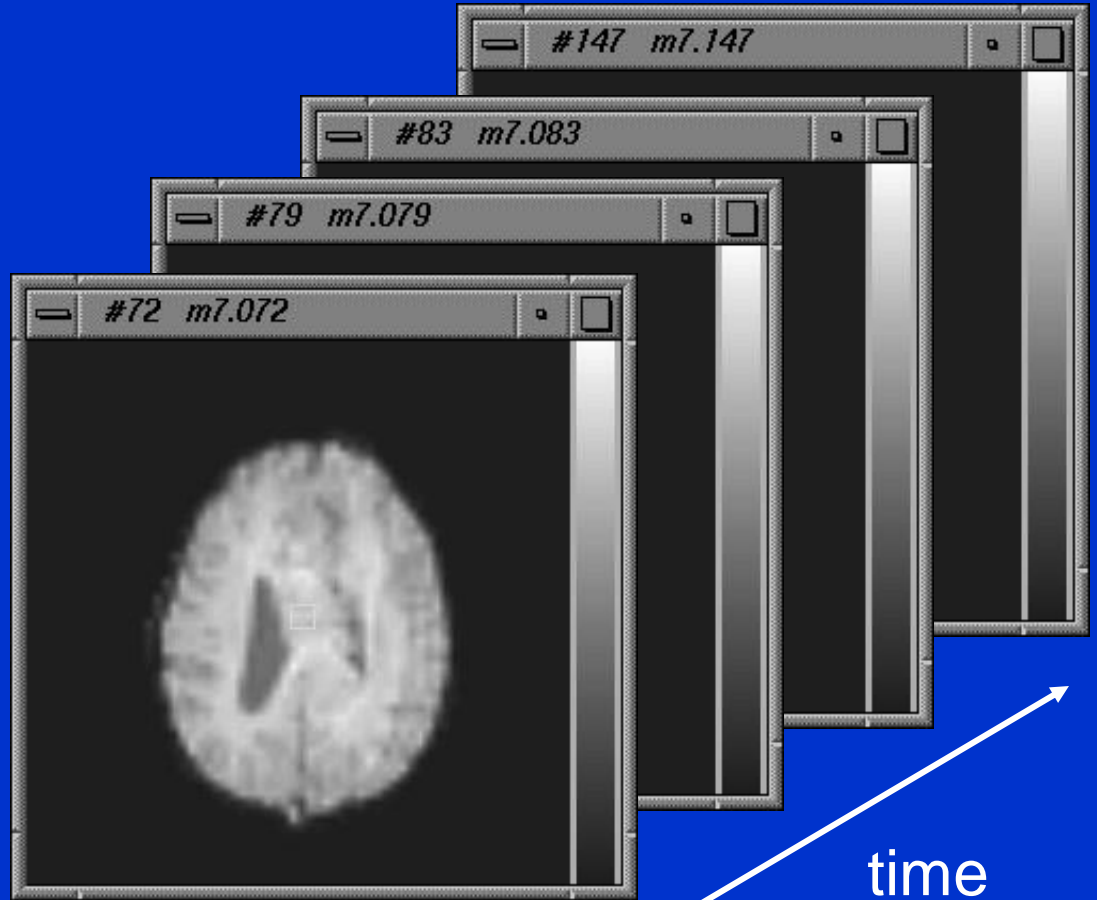


Contrast in Functional MRI

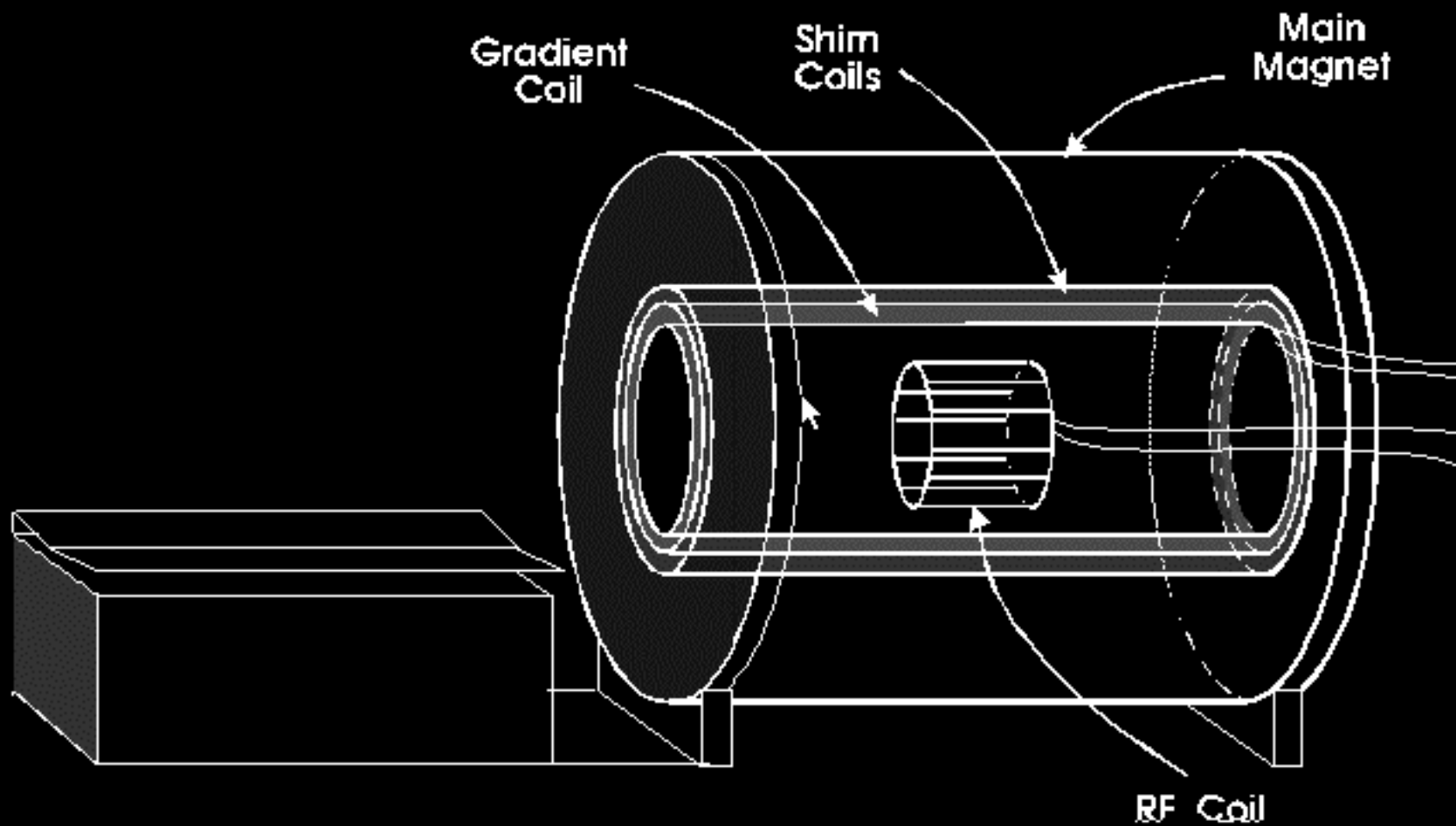
- **Blood Volume**
- **Blood Oxygenation**
- **Perfusion**
- **Metabolism**




Anatomic



Functional



Local gradients solved the problem



August, 1991

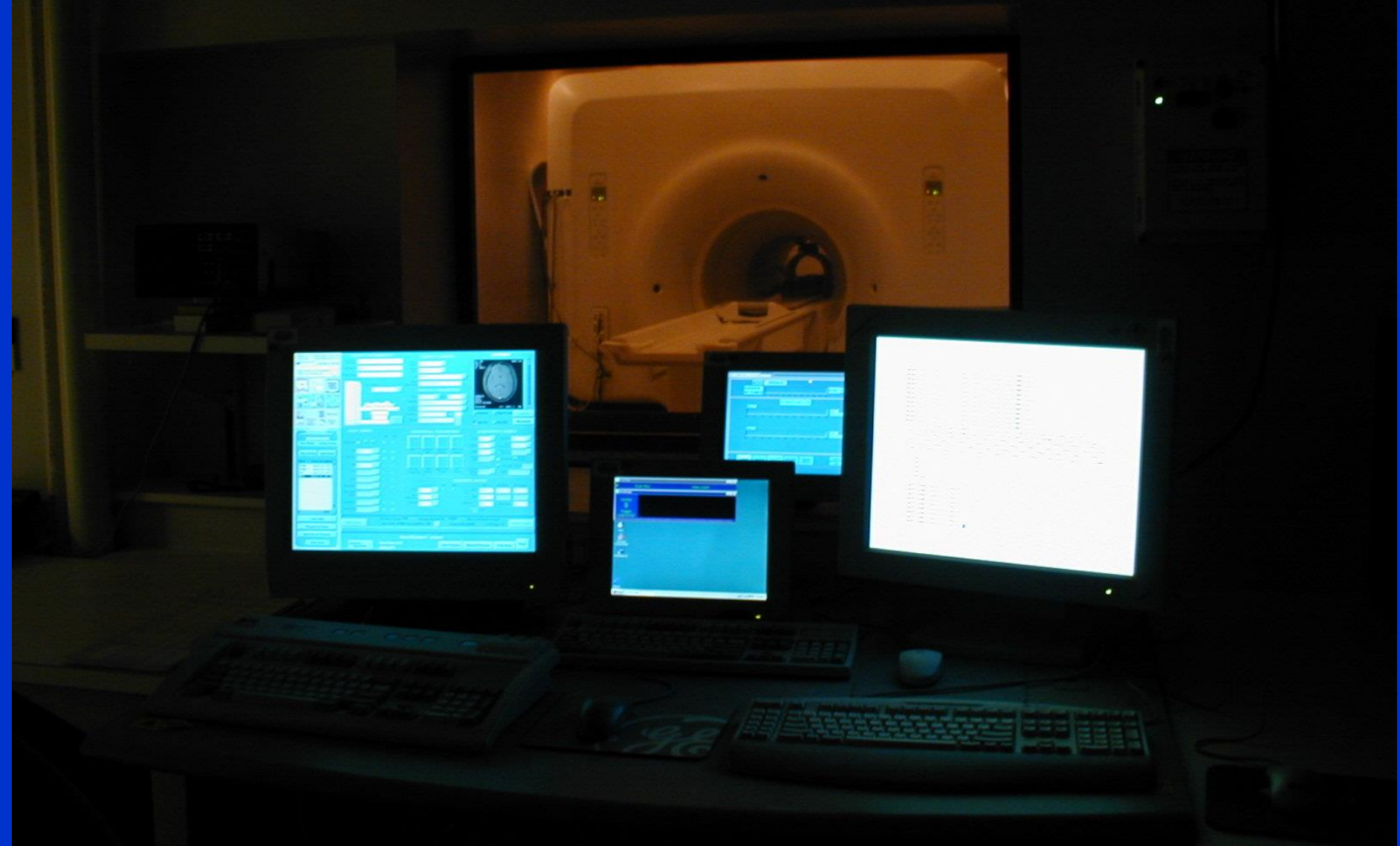1991-1992



1992-1999



General Electric 3 Tesla Scanner

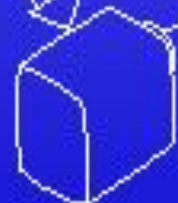

MRI Instrumentation

Computer
Graphics



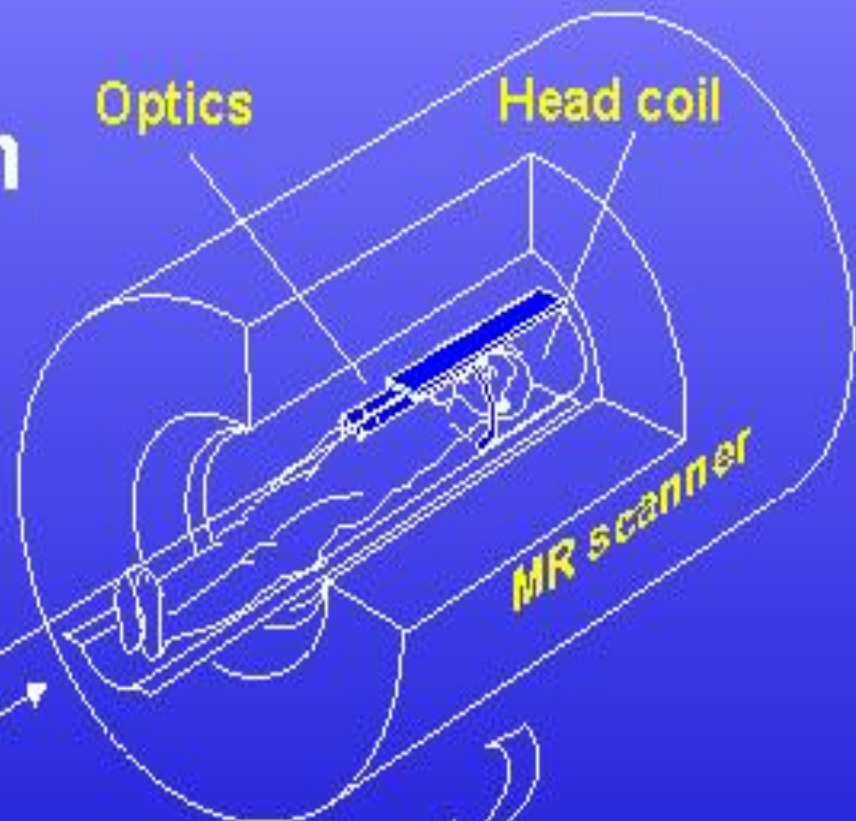
VCR



Video Image
Source

Optics

Head coil



16"



Baseline Task



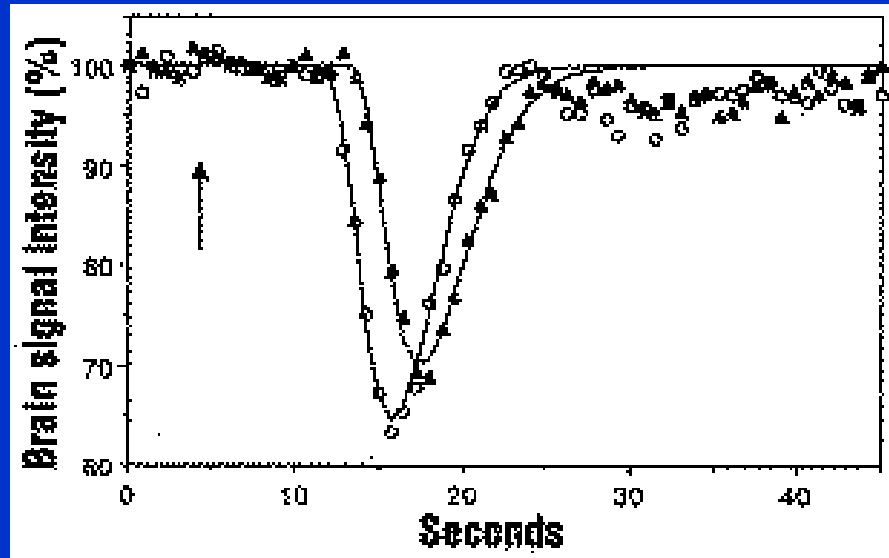


Experimental Task



Blood Volume Changes with Brain Activation

Resting

Active

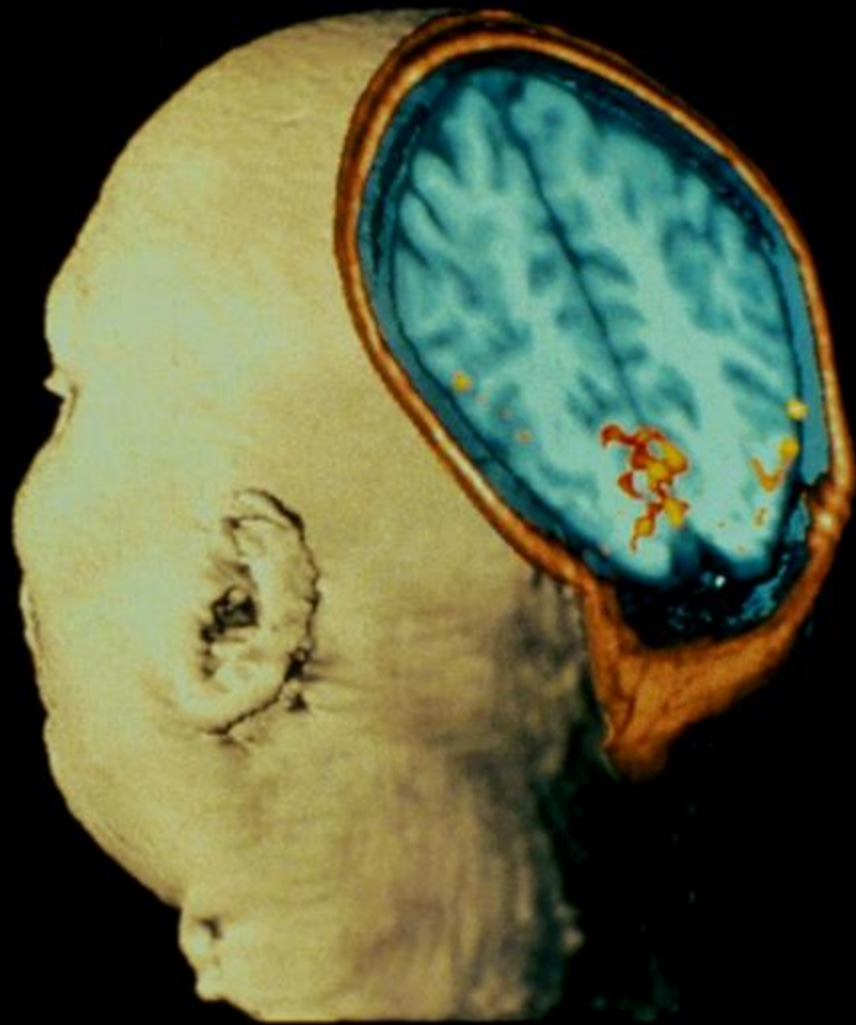


Photic Stimulation

MRI Image showing
activation of the
Visual Cortex

From Belliveau, et al.
Science Nov 1991

MSC - perfusion



BOLD Contrast in the Detection of Neuronal Activity

Cerebral Tissue Activation



Local Vasodilation



Increase in Cerebral Blood Flow and Volume



Oxygen Delivery Exceeds Metabolic Need



Increase in Capillary and Venous Blood Oxygenation



Decrease in Deoxy-hemoglobin



Decrease in susceptibility-related intravoxel dephasing

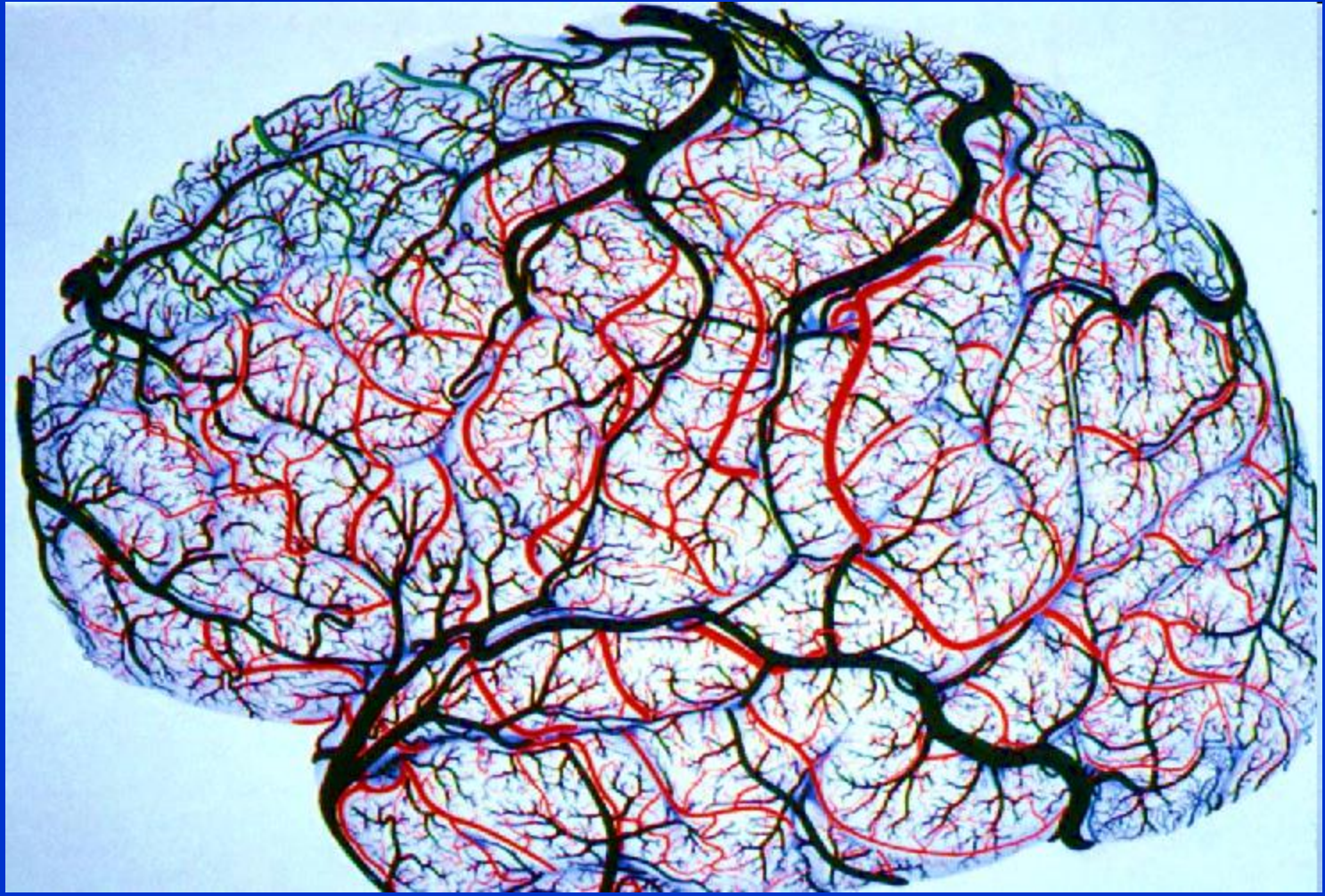


Increase in T2 and T2*



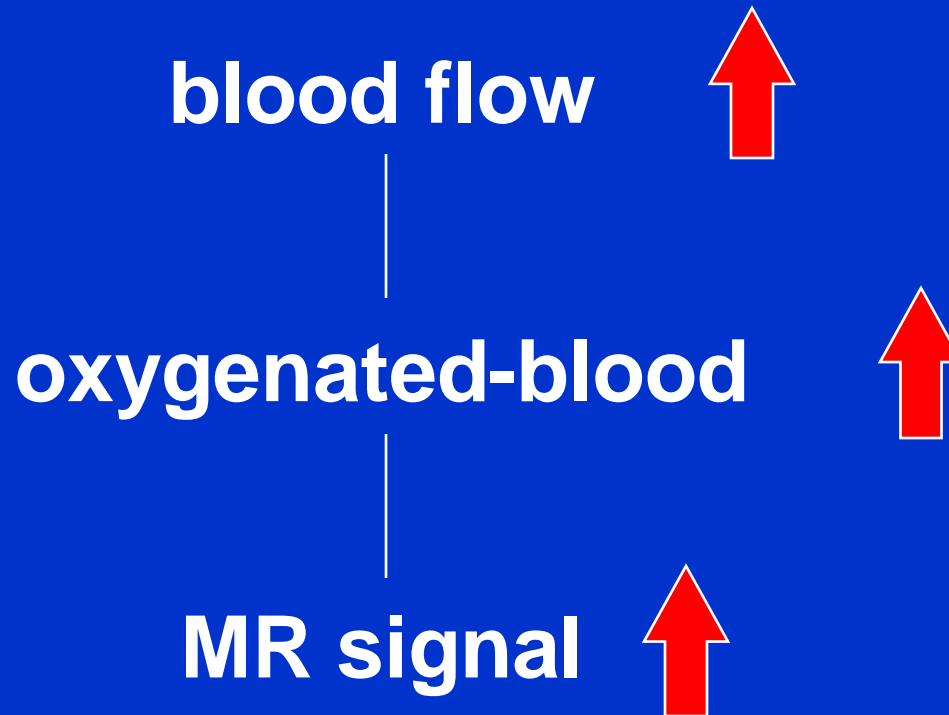
Local Signal Increase in T2 and T2* - weighted sequences

Deoxy-hemoglobin: paramagnetic
Oxy-hemoglobin: diamagnetic

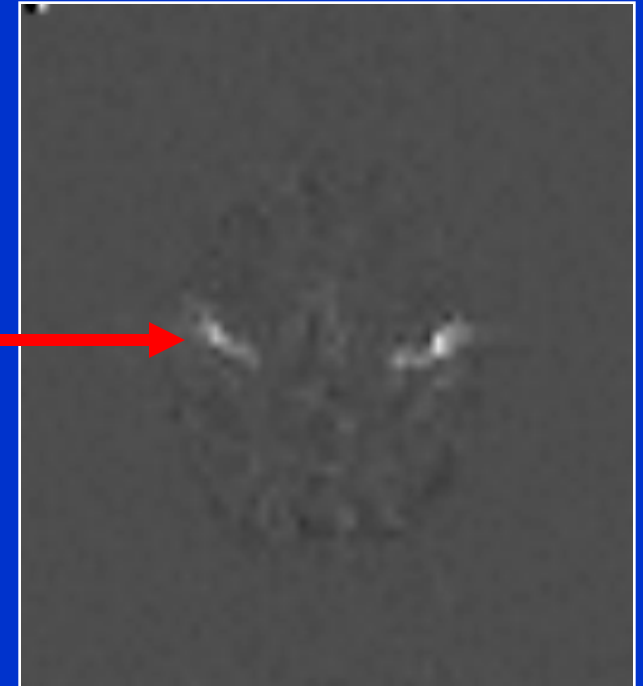
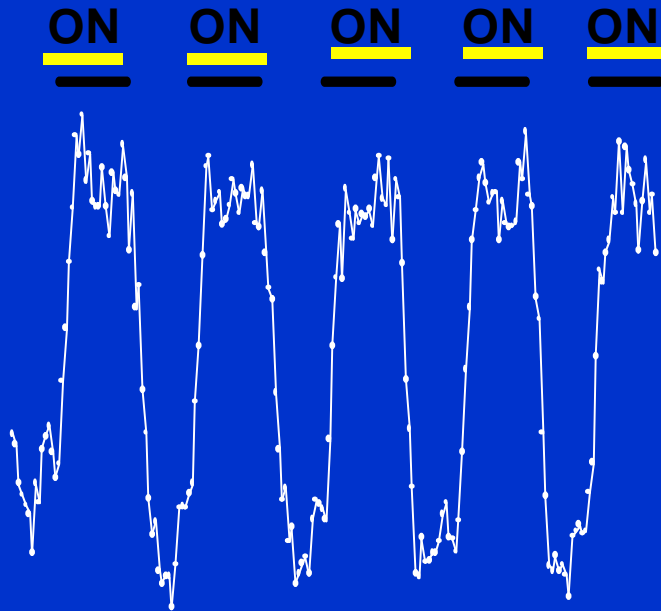


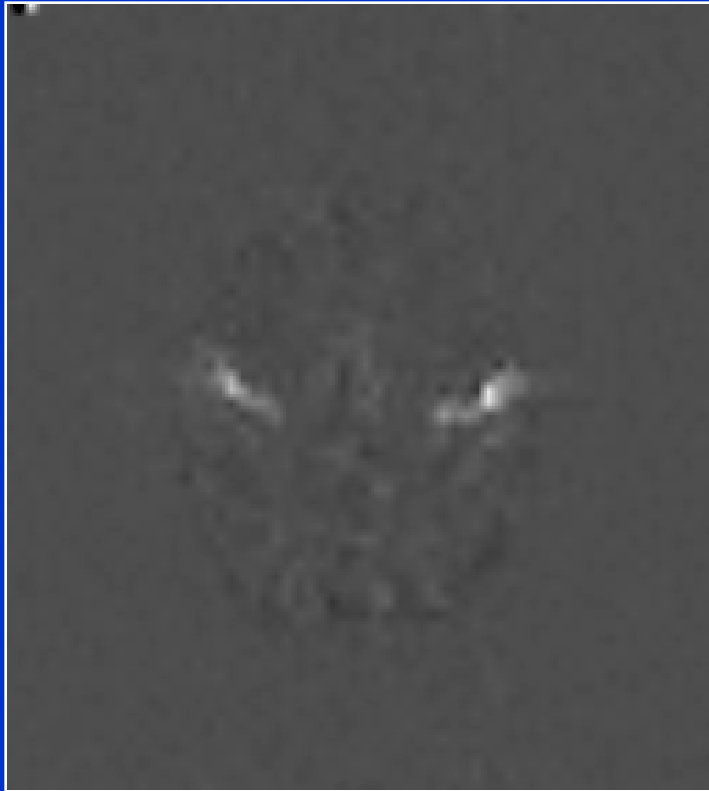BOLD

(blood oxygenation level dependence)

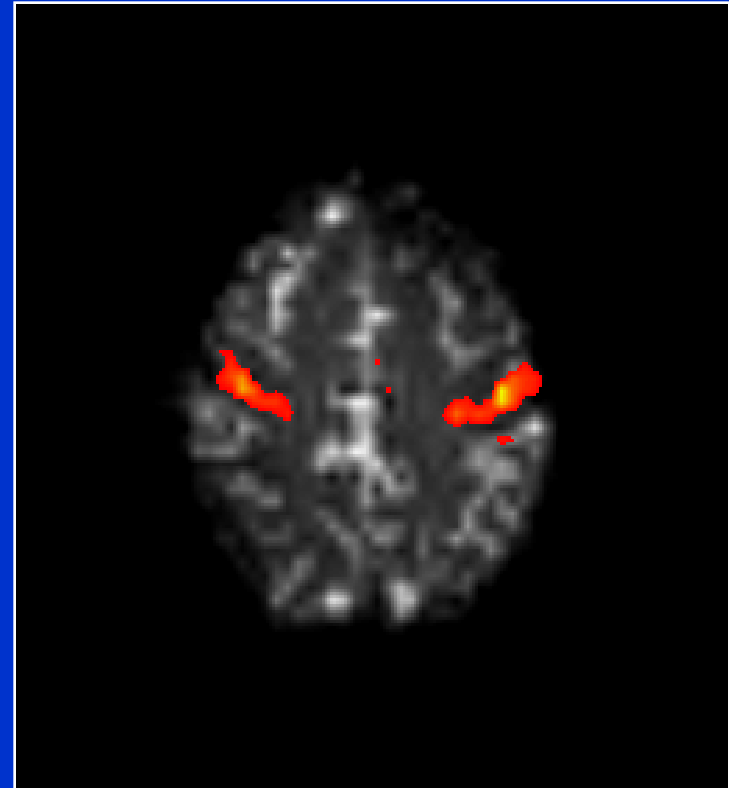


BOLD: Motor Cortex Activation





Cross Correlation Image

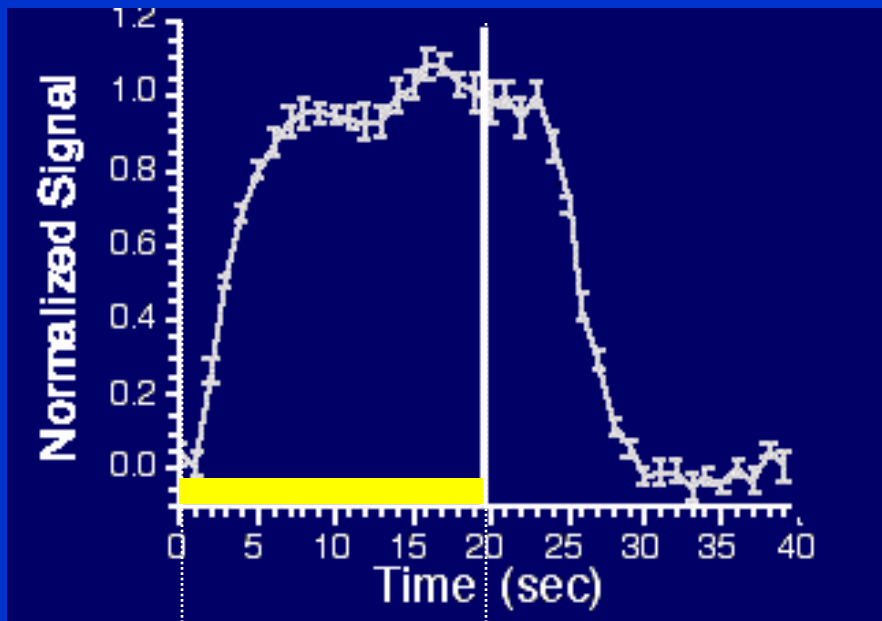


Cross Correlation Image
Anatomical Image

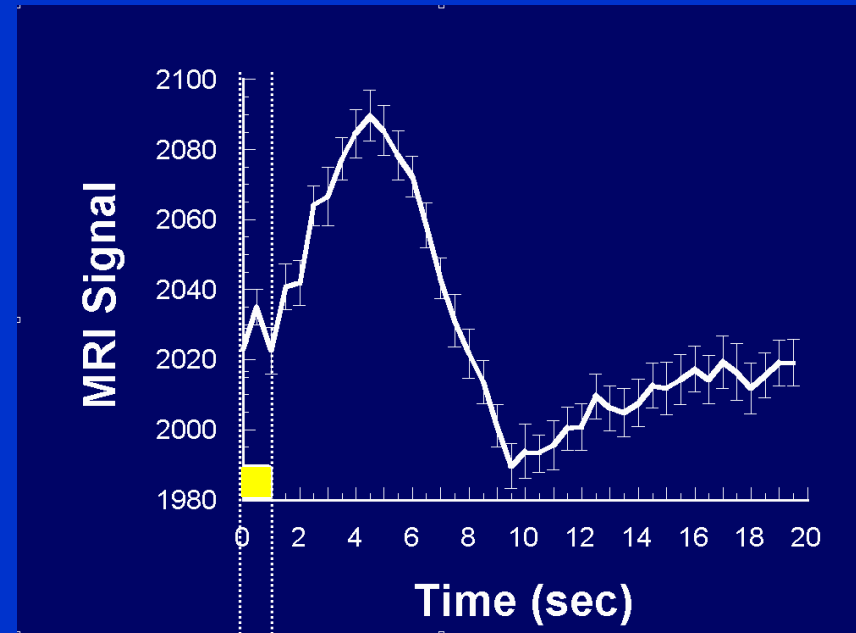


The BOLD Signal

Blood Oxygenation Level Dependent (BOLD) signal changes



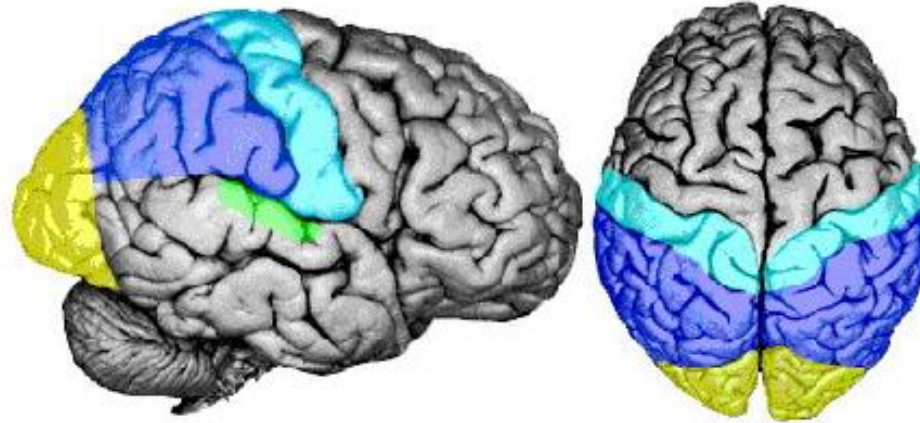
task



task

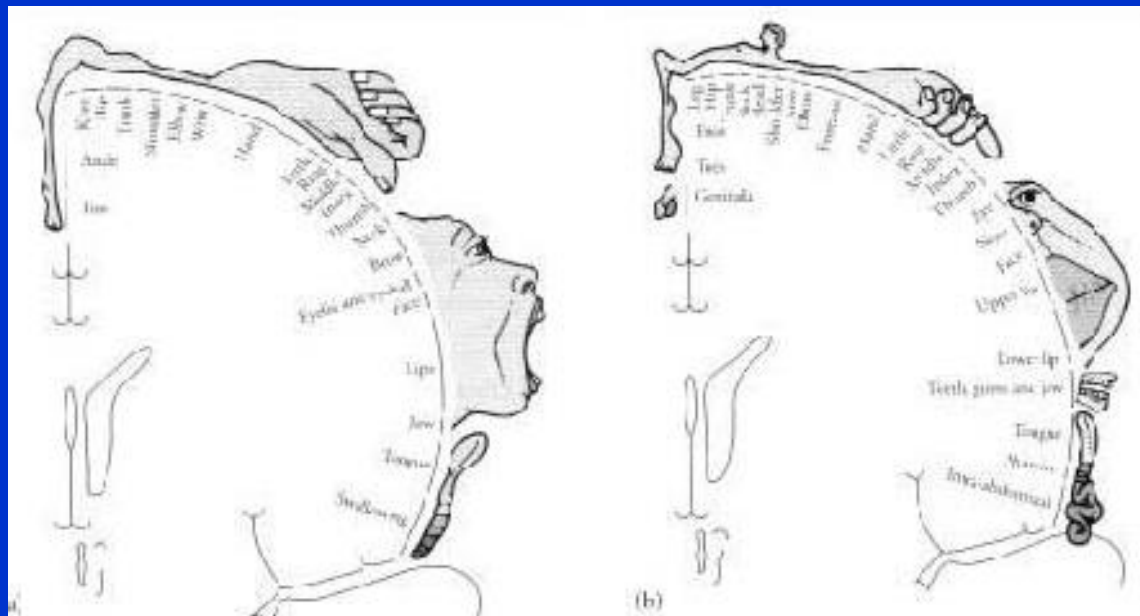
Alternating Left and Right Finger Tapping





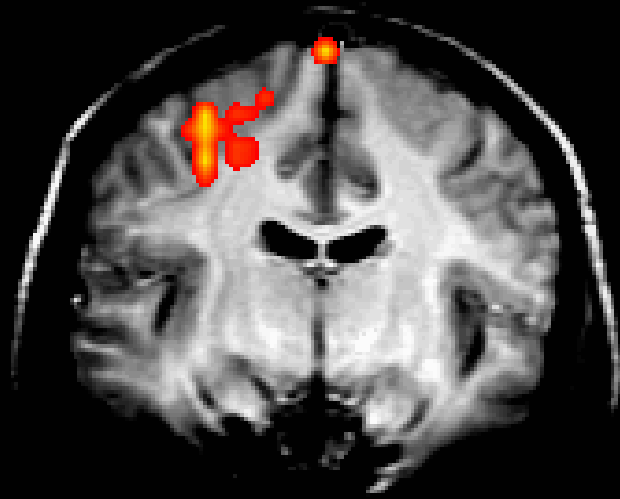■ Parietal/
Somatosensory
■ Parietal/
Association Area

■ Occipital/Vision
■ Auditory

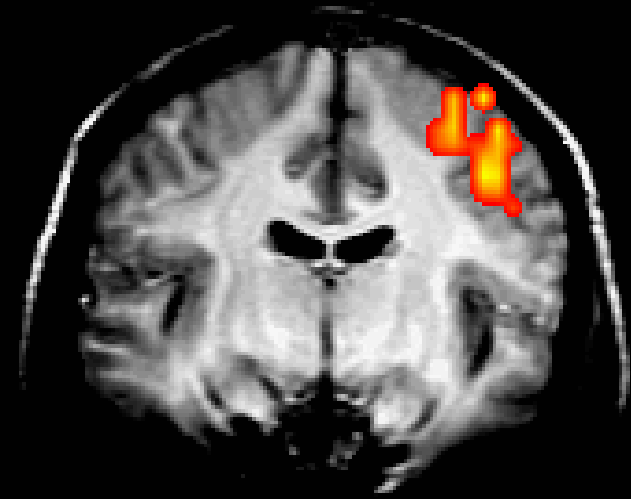


Finger Movement

Left

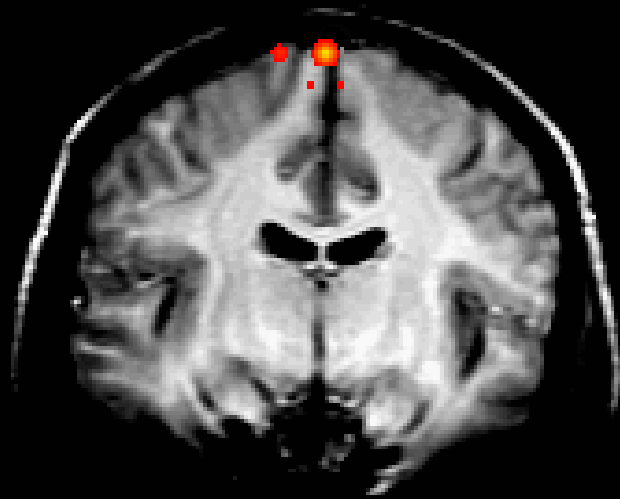


Right

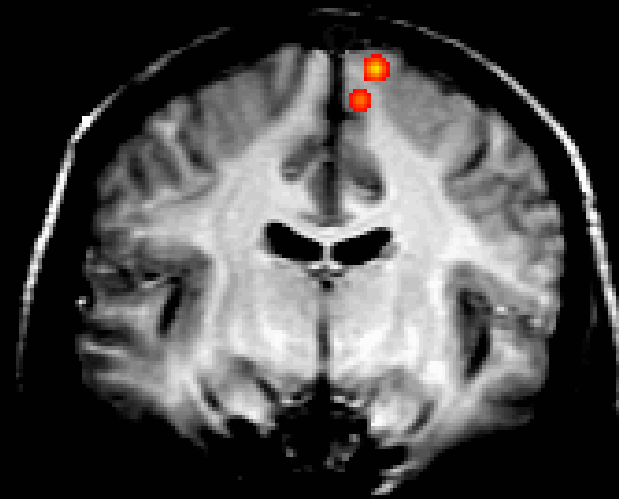


Toe Movement

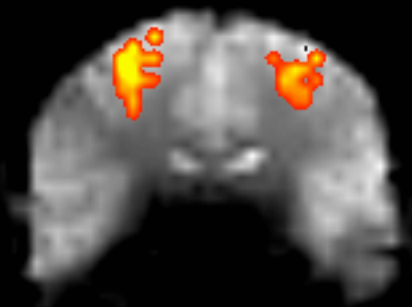Left



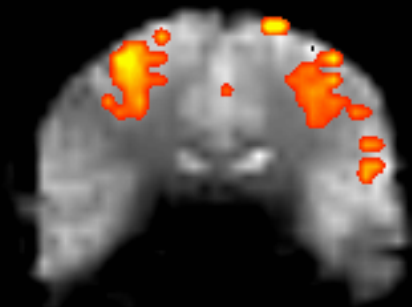
Right



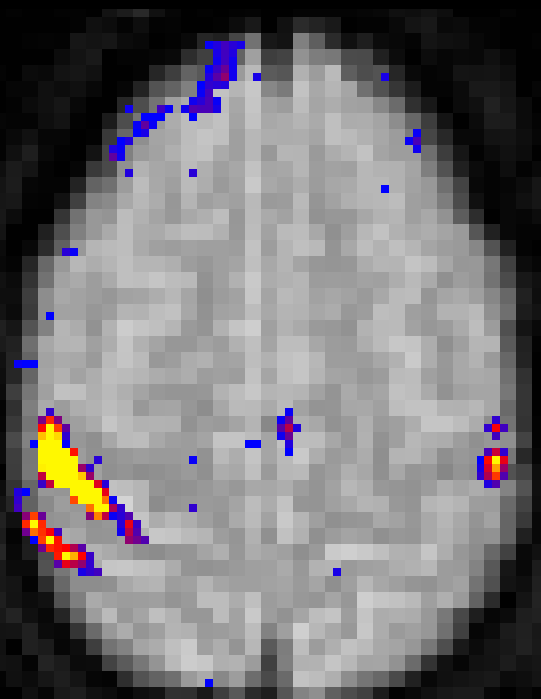
Wrist



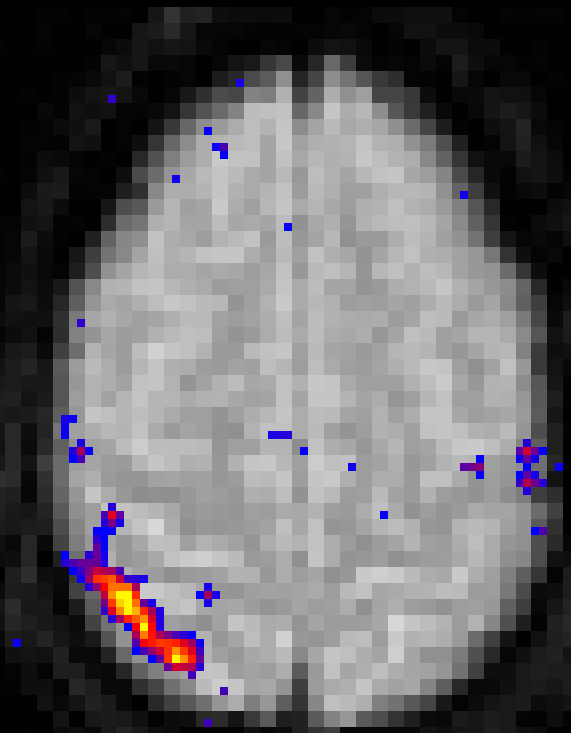
Fingers



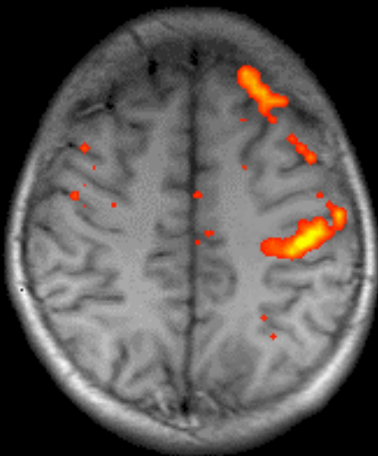
Finger Movement



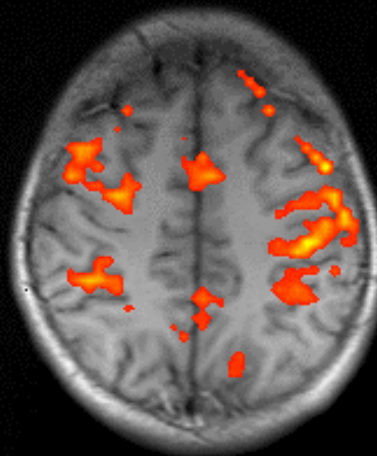
Tactile Stimulation



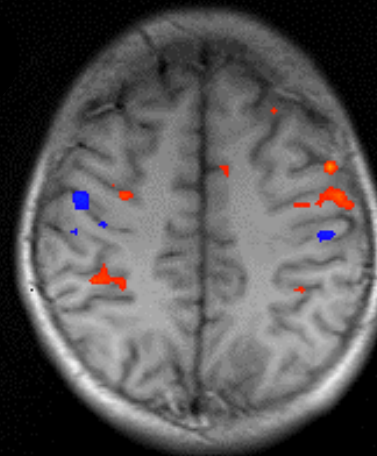
Simple Right



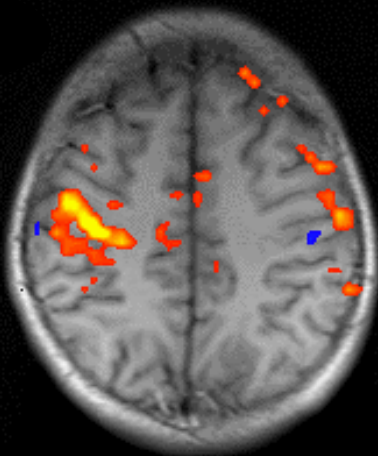
Complex Right



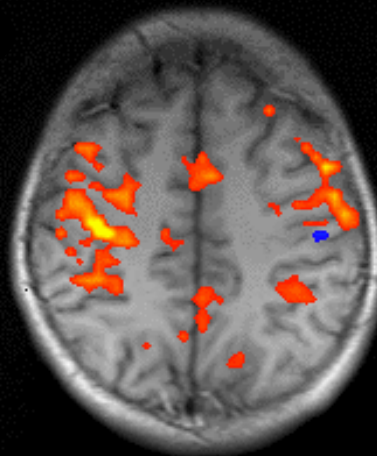
Imagined
Complex Right



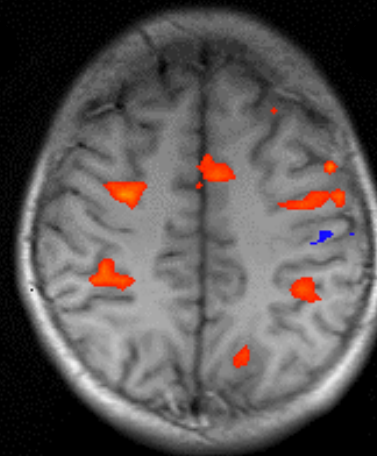
Simple Left



Complex Left

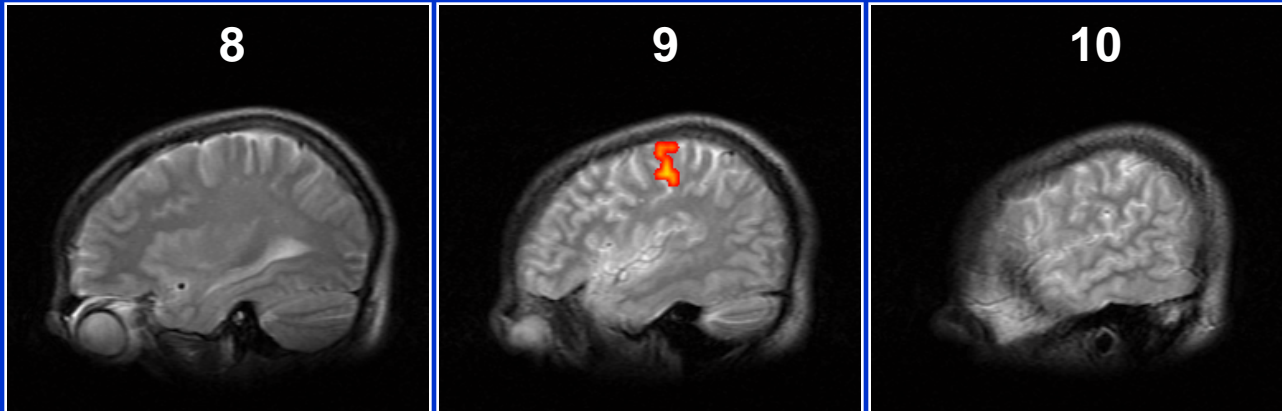
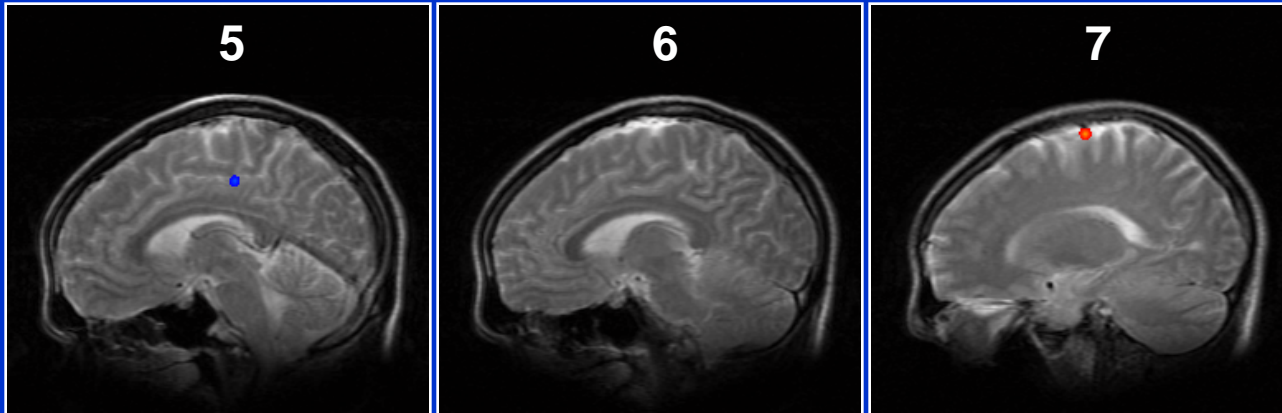
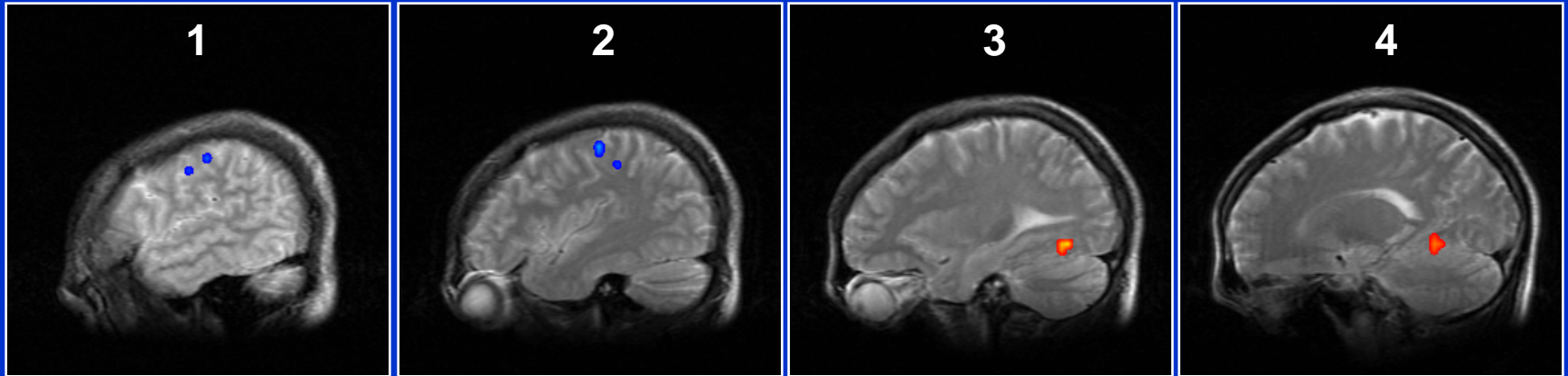


Imagined
Complex Left



Left

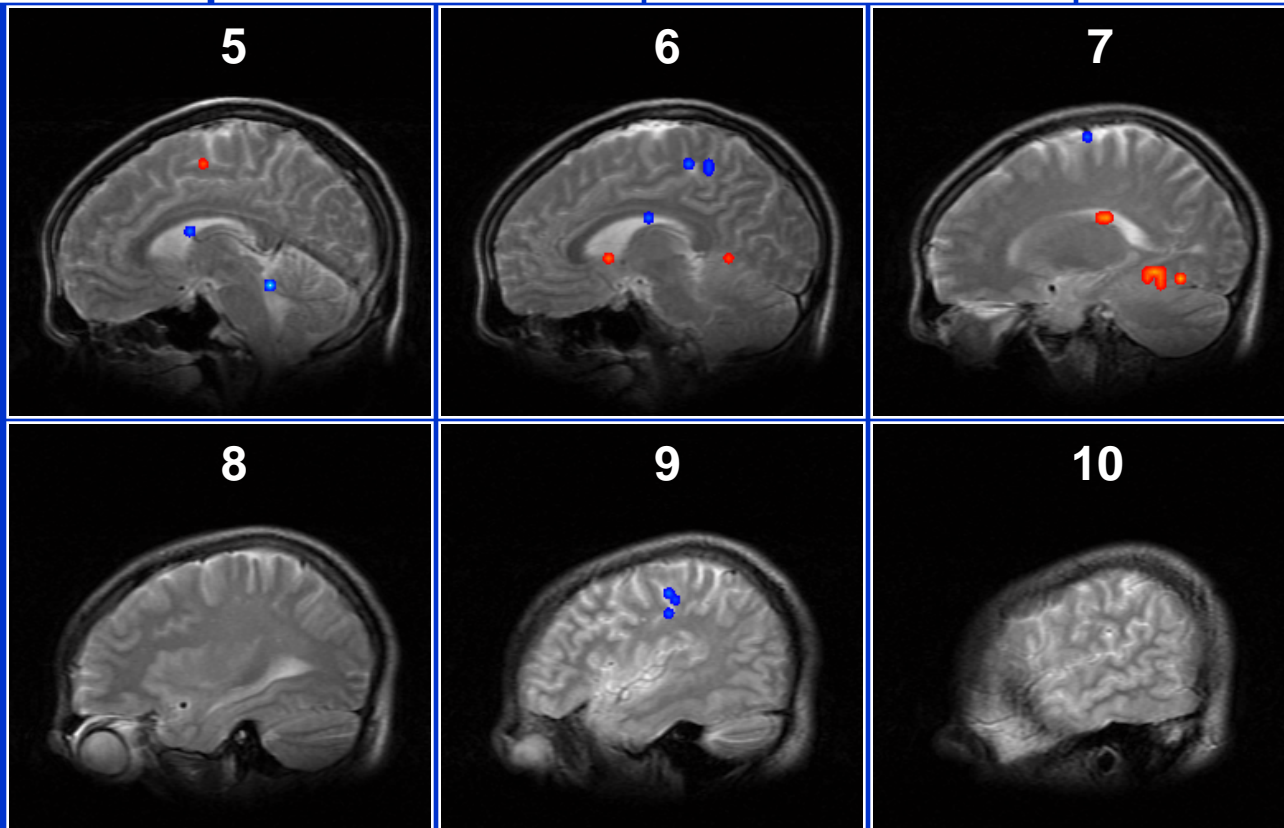
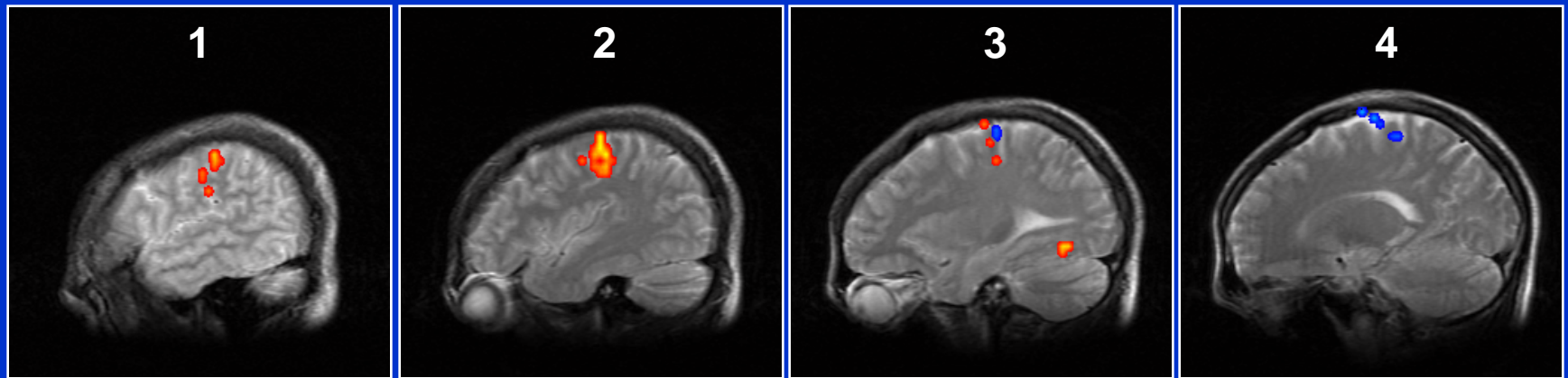
Simple Finger Movement on the Left Hand



Right

Left

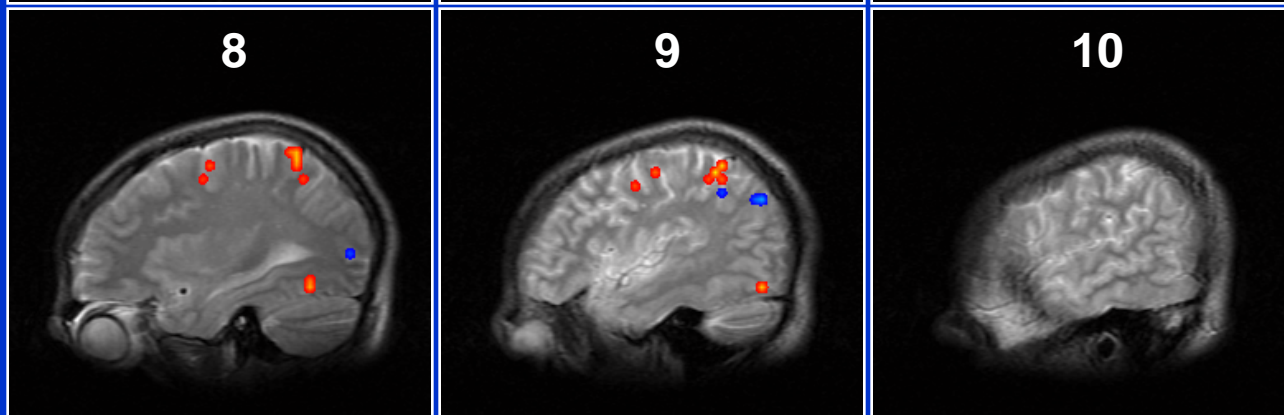
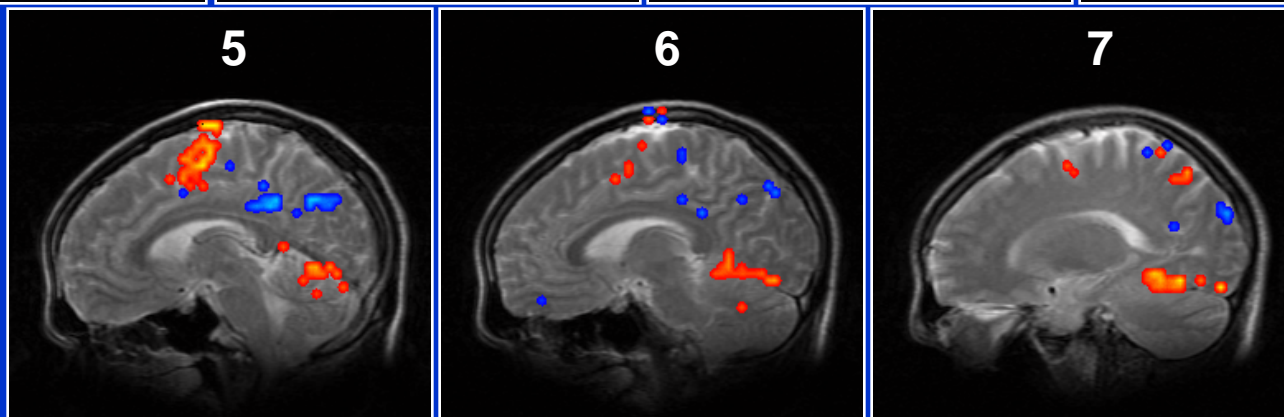
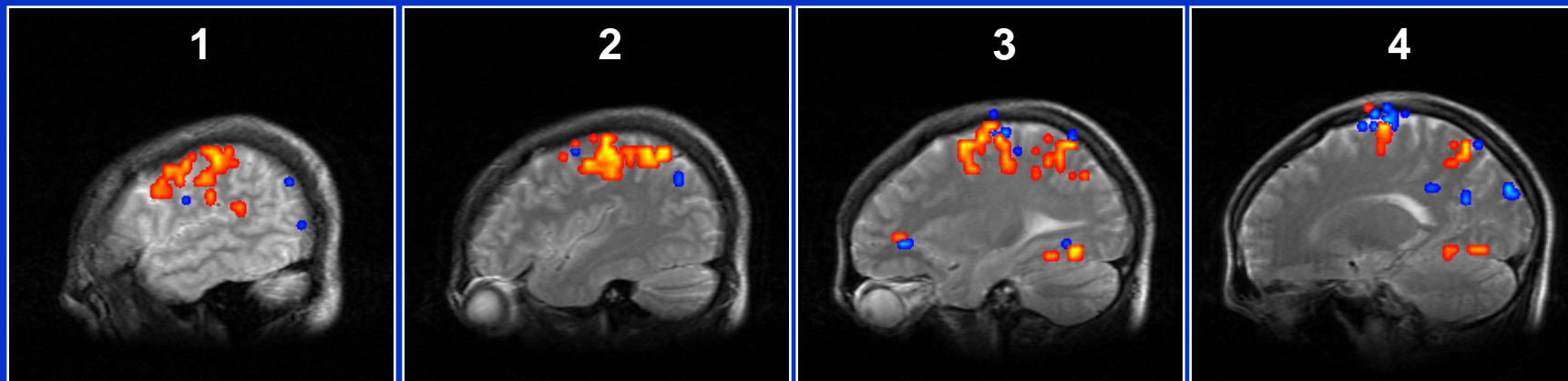
Simple Finger Movement on the Right Hand



Right

Left

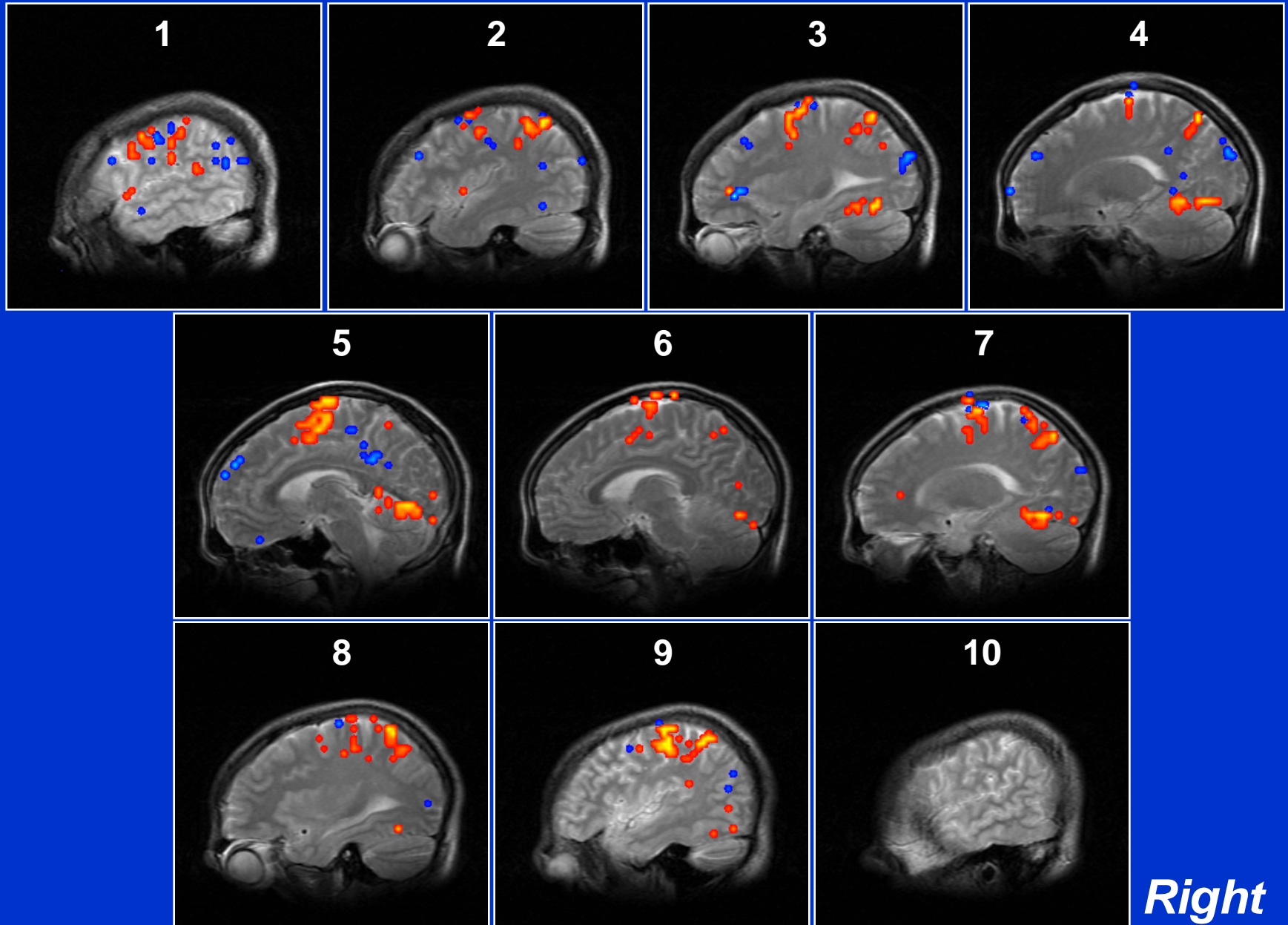
Complex Finger Movement on the Right Hand



Right

Left

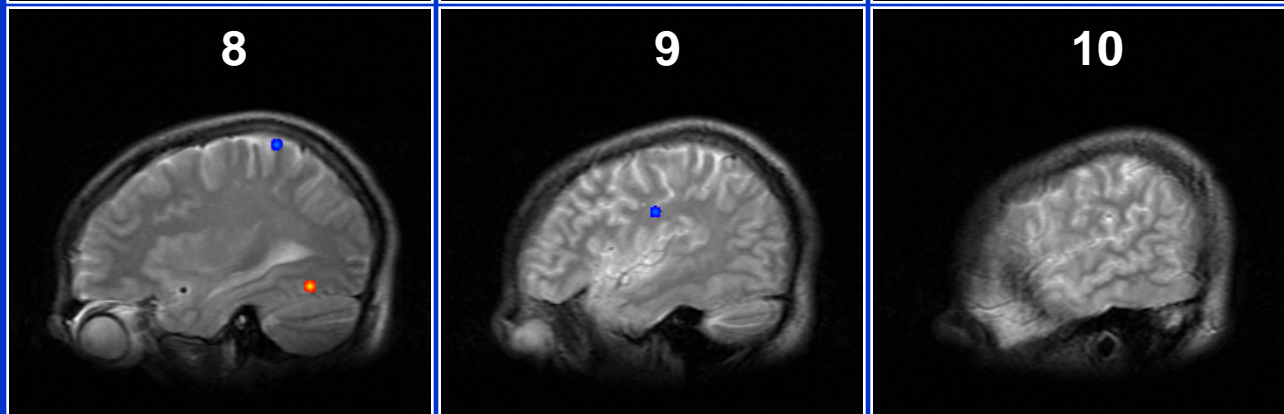
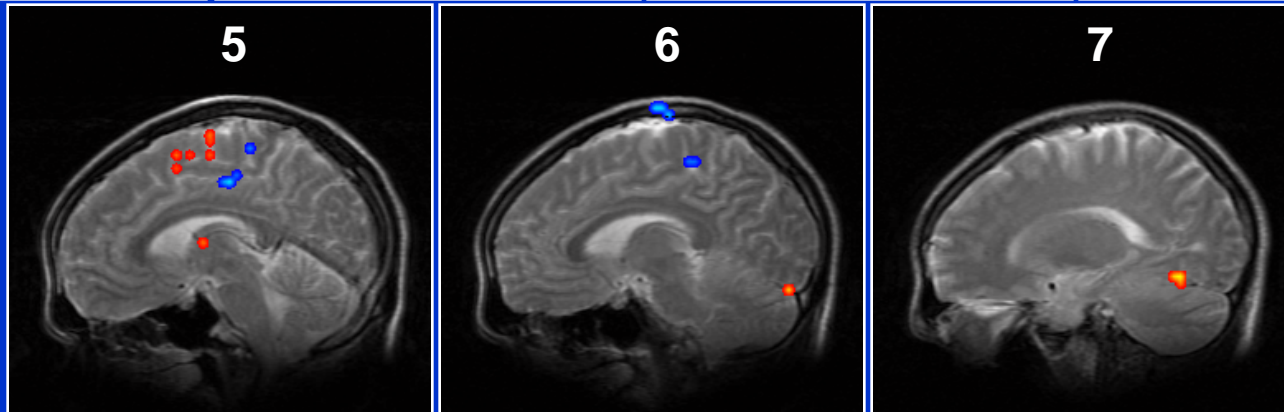
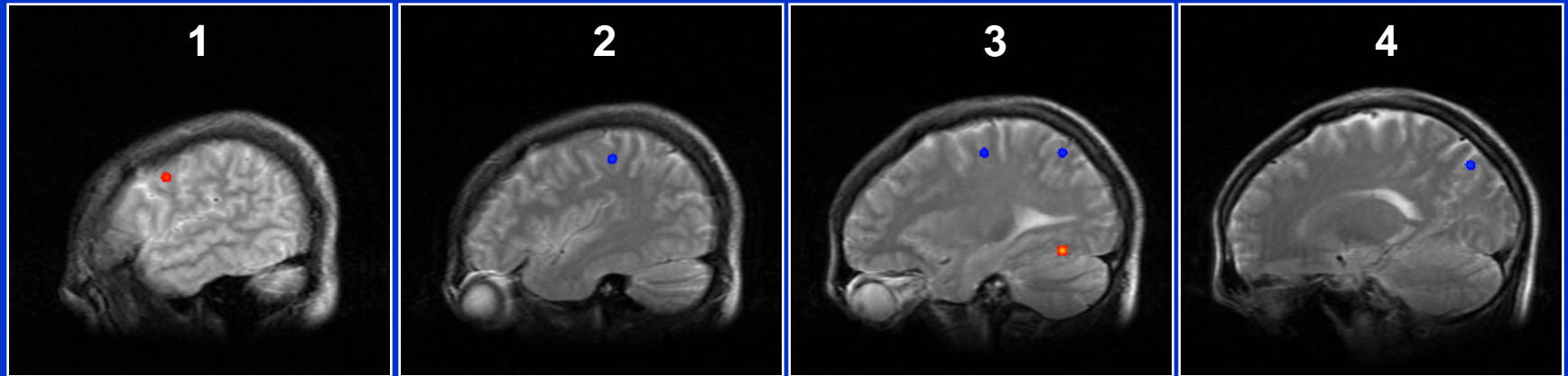
Complex Finger Movement on the Left Hand



Right

Left

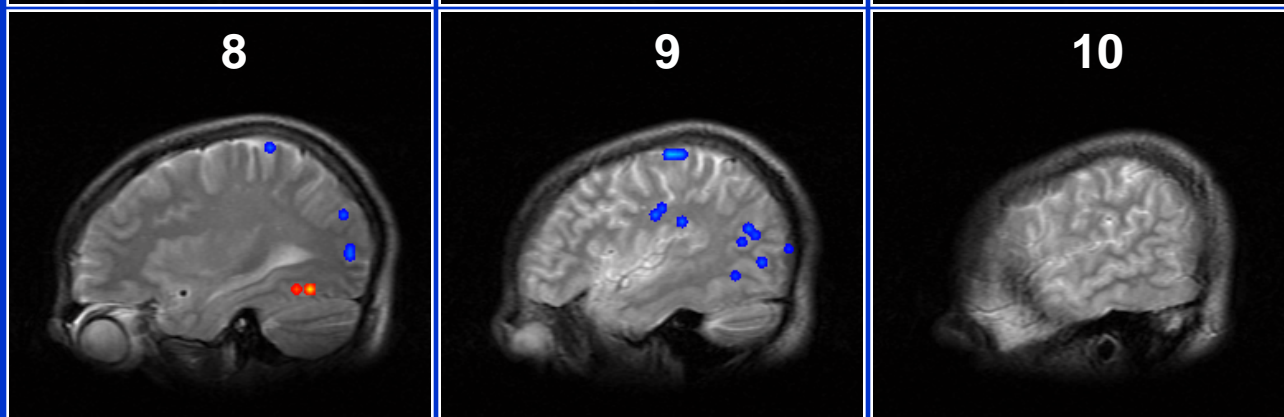
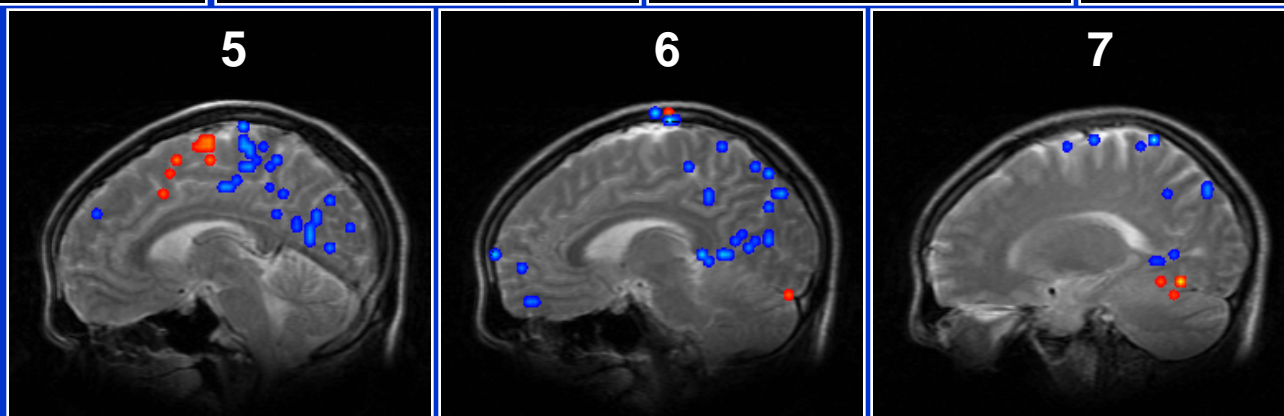
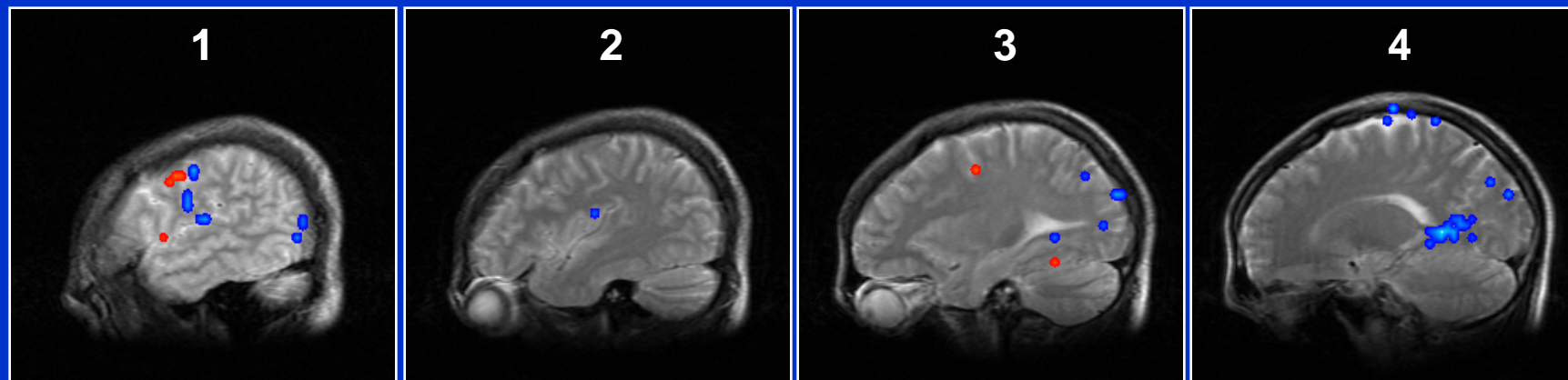
Imagined Complex Finger Movement on the Left Hand



Right

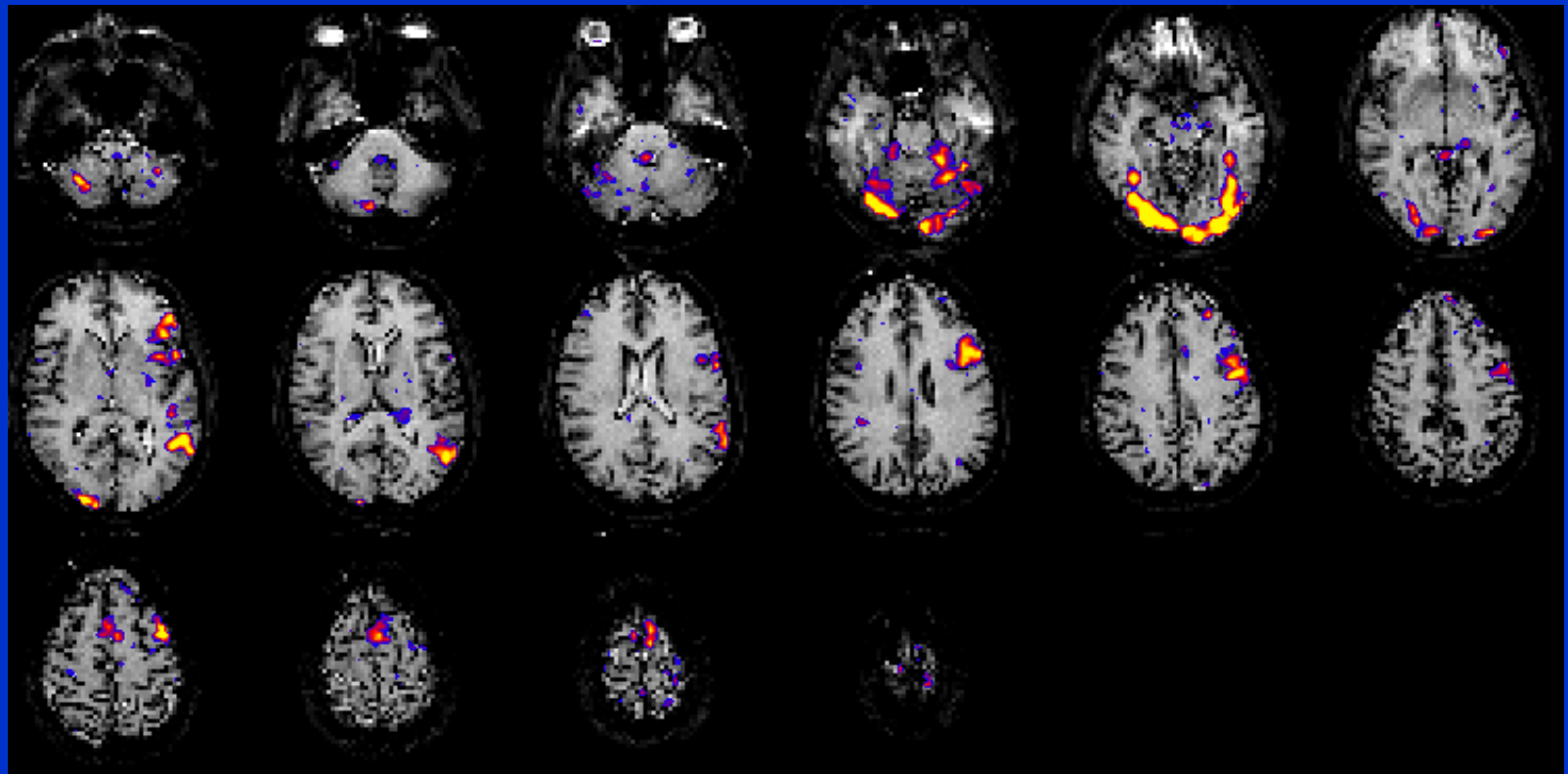
Left

Imagined Complex Finger Movement on the Right Hand

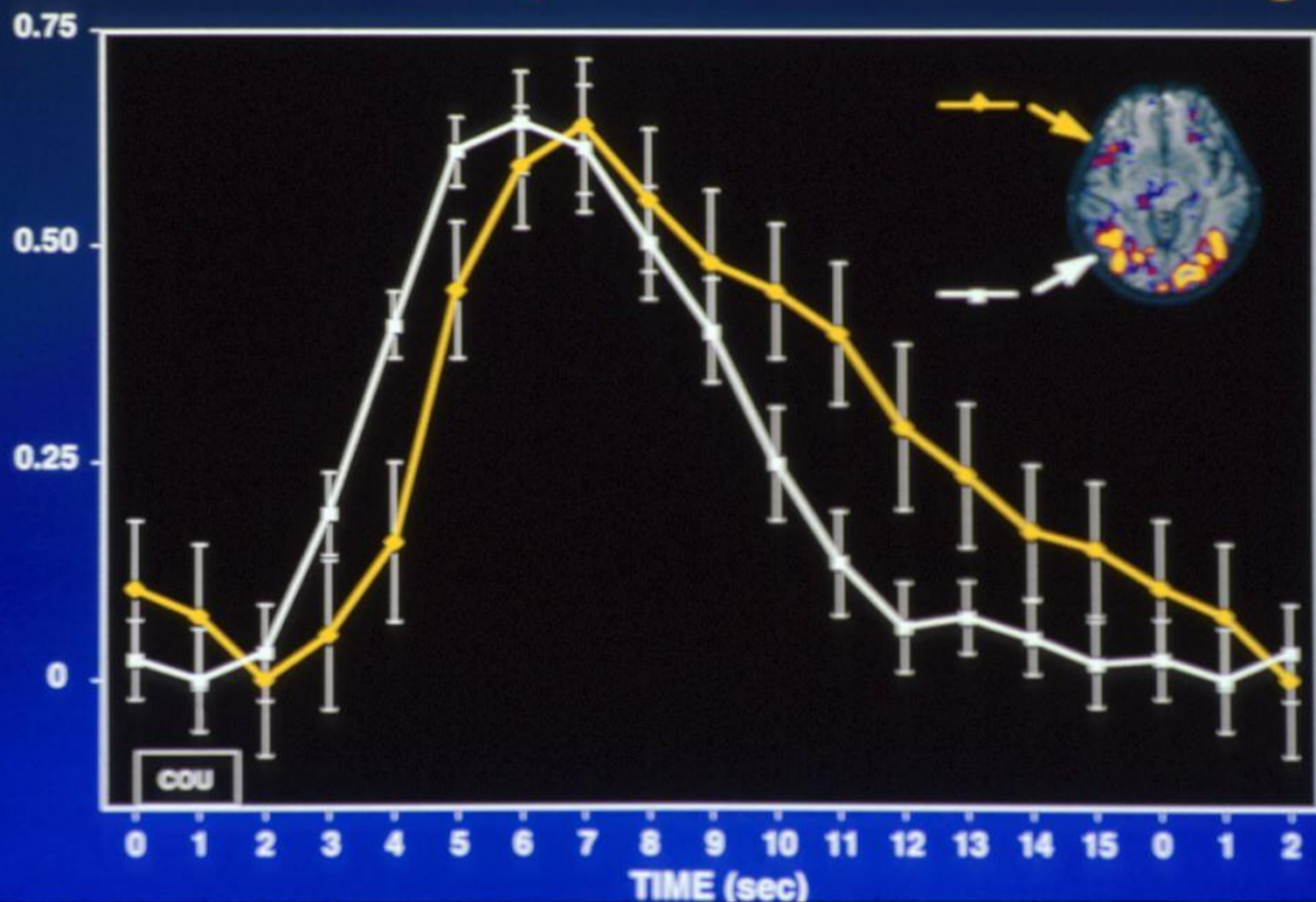


Right

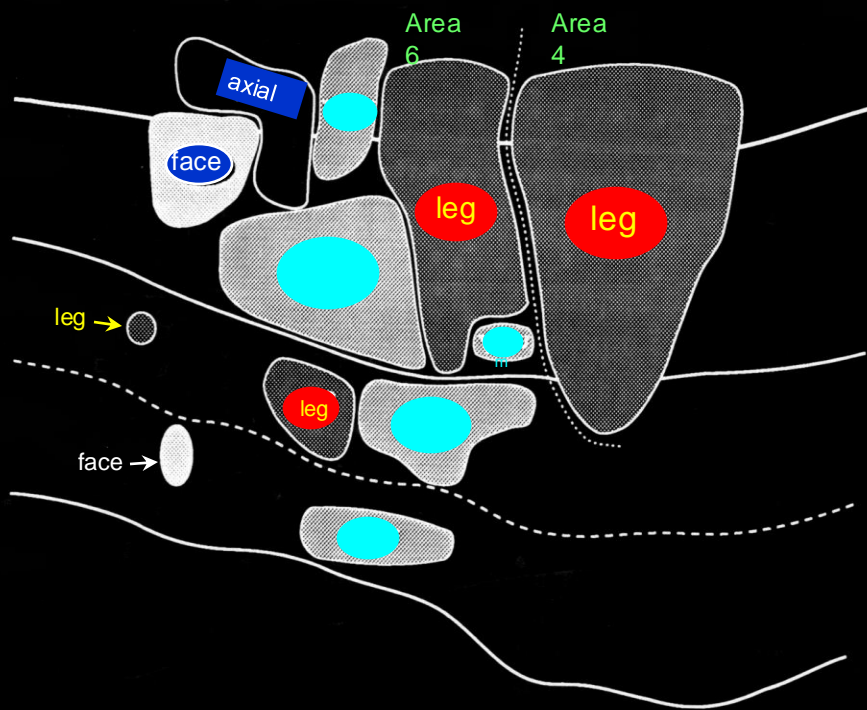
Word stem completion



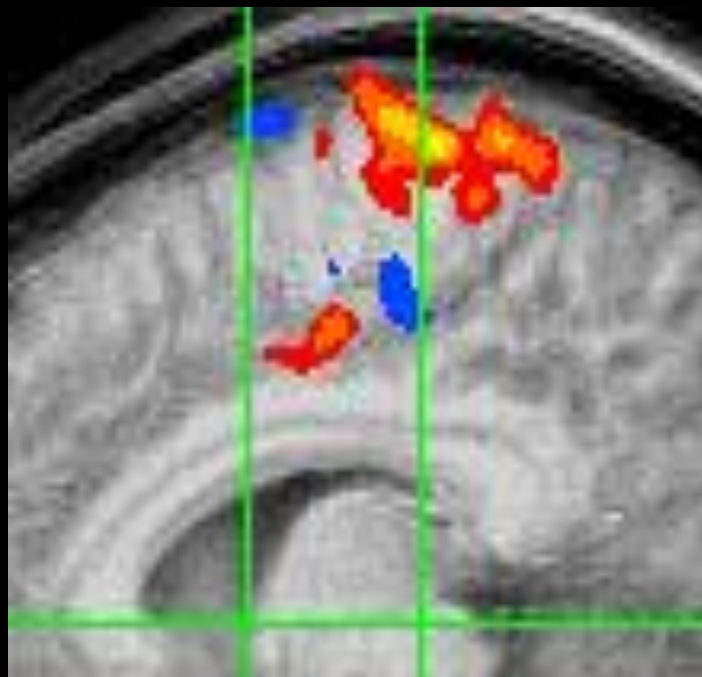
Time Course Comparison Across Brain Regions



FMRI of Leg Motor Topography - Medial Wall

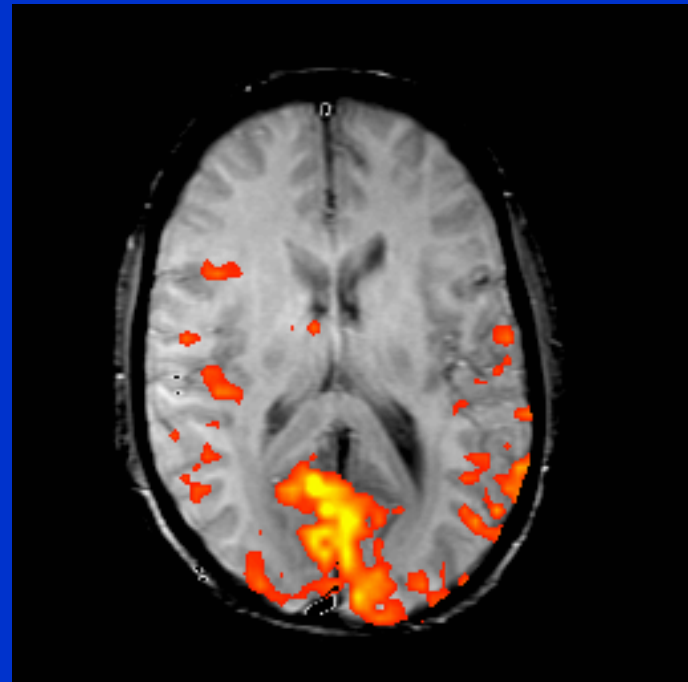
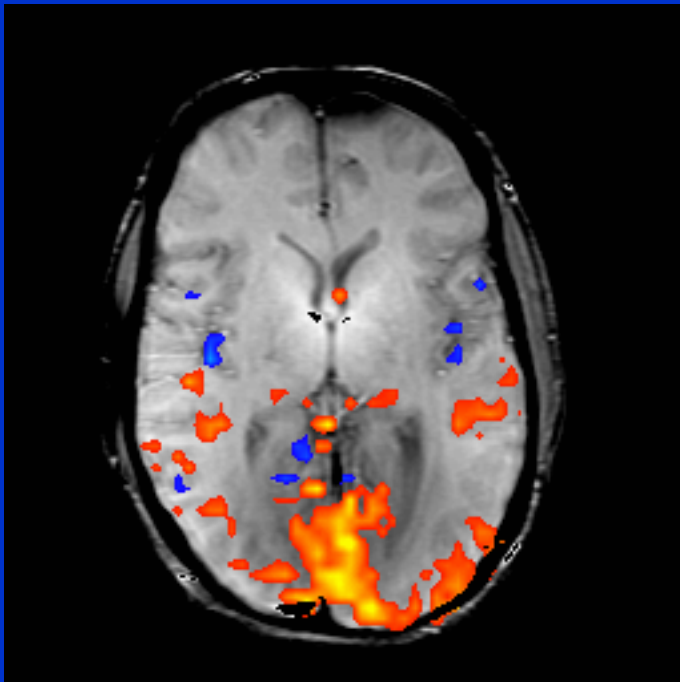


Macaque

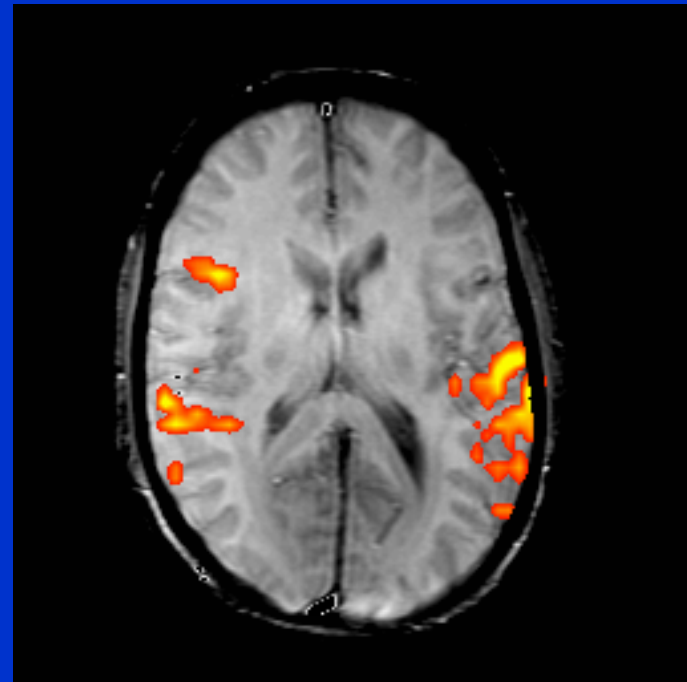
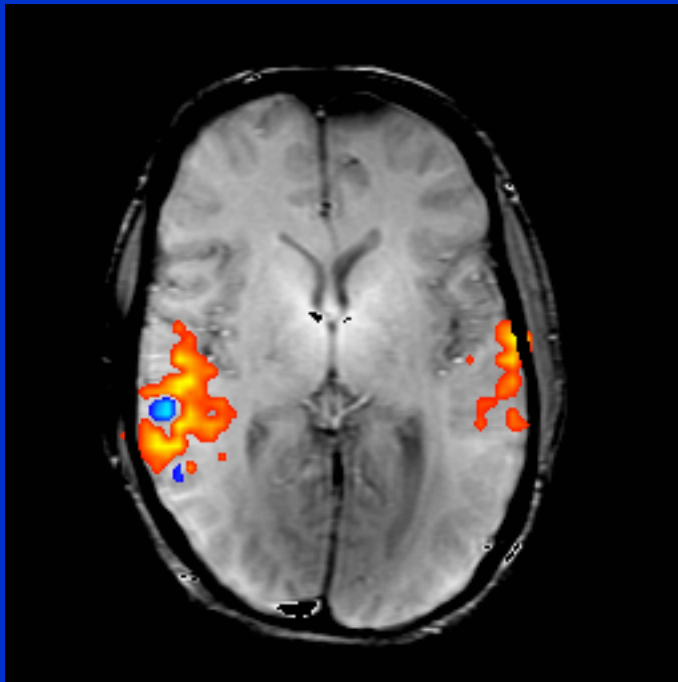


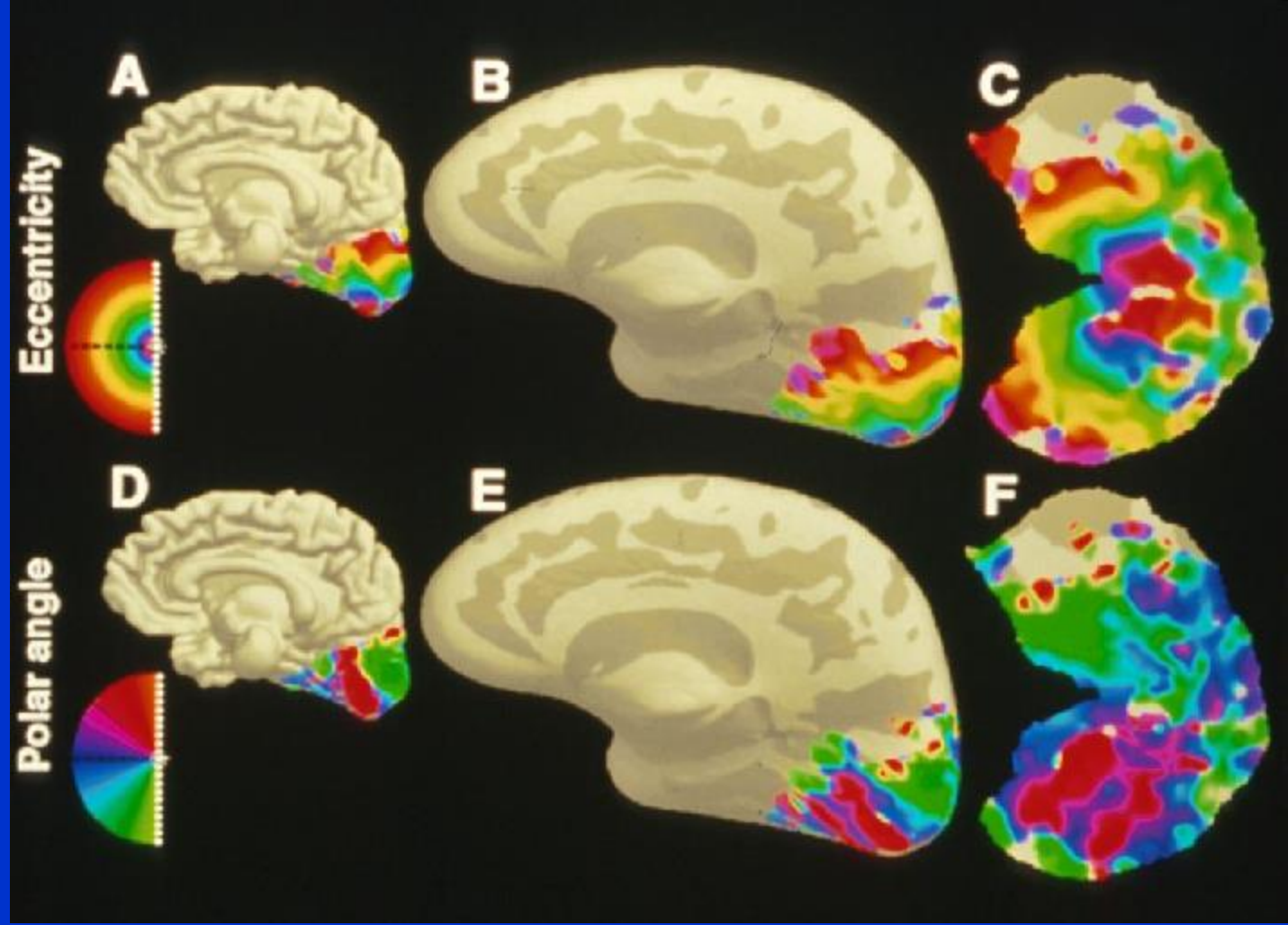
Human

Reading

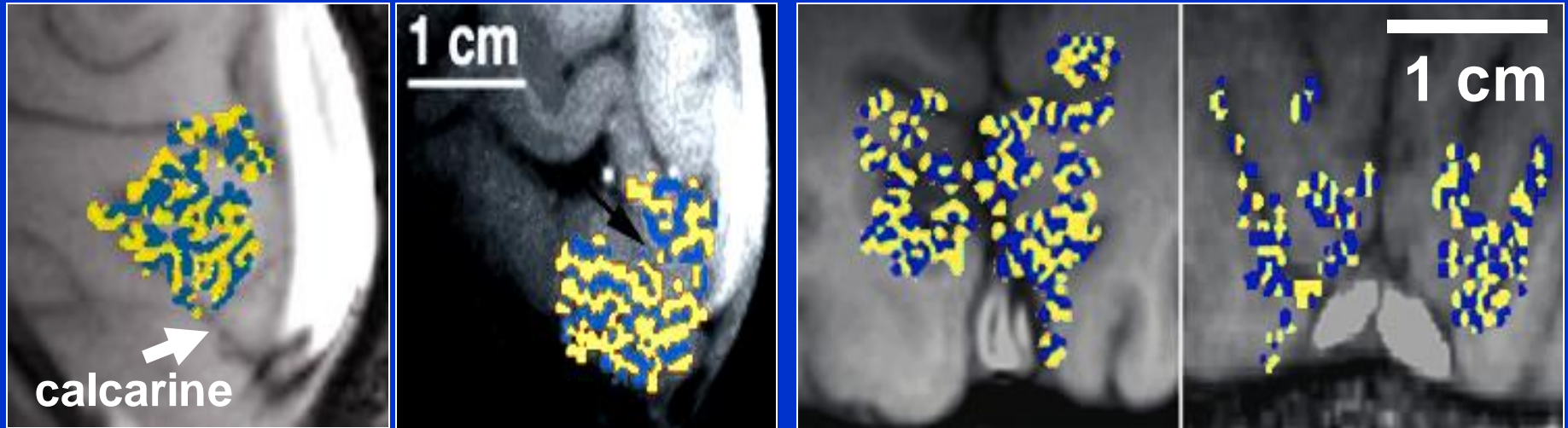


Listening to Spoken Words





ODC Maps using fMRI



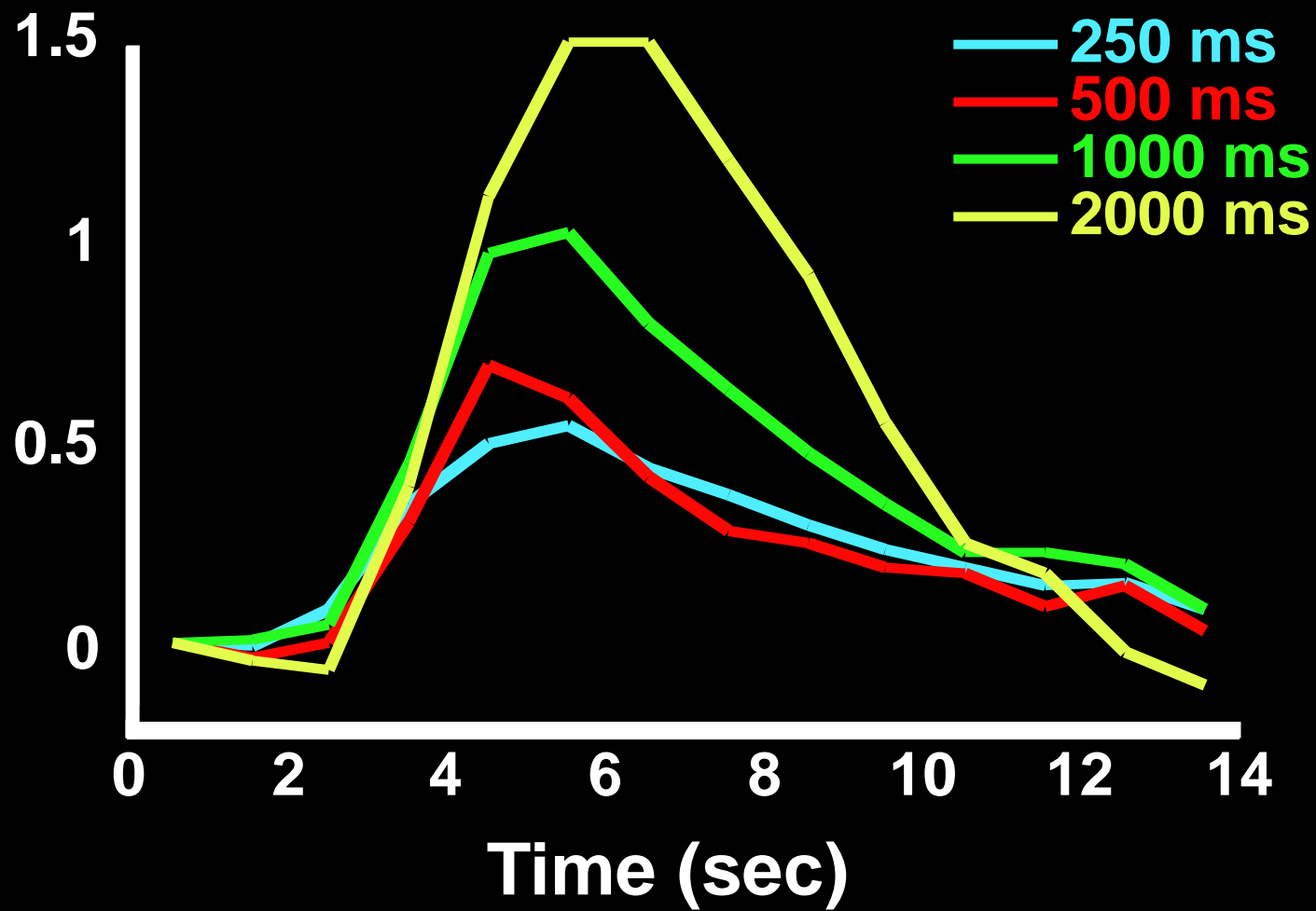
- Identical in size, orientation, and appearance to those obtained by optical imaging¹ and histology^{3,4}.

Menon et al.

¹Malonek D, Grinvald A. *Science* 272, 551-4 (1996).

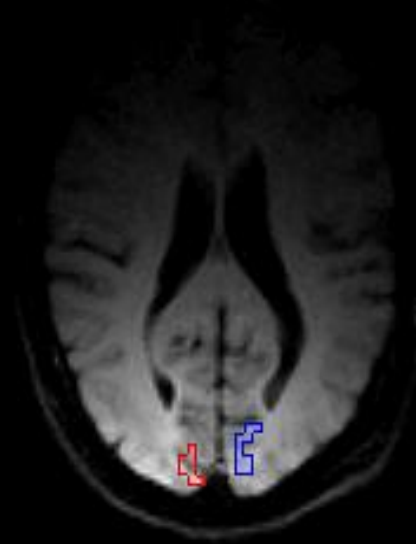
³Horton JC, Hocking DR. *J Neurosci* 16, 7228-39 (1996).

⁴Horton JC, et al. *Arch Ophthalmol* 108, 1025-31 (1990).

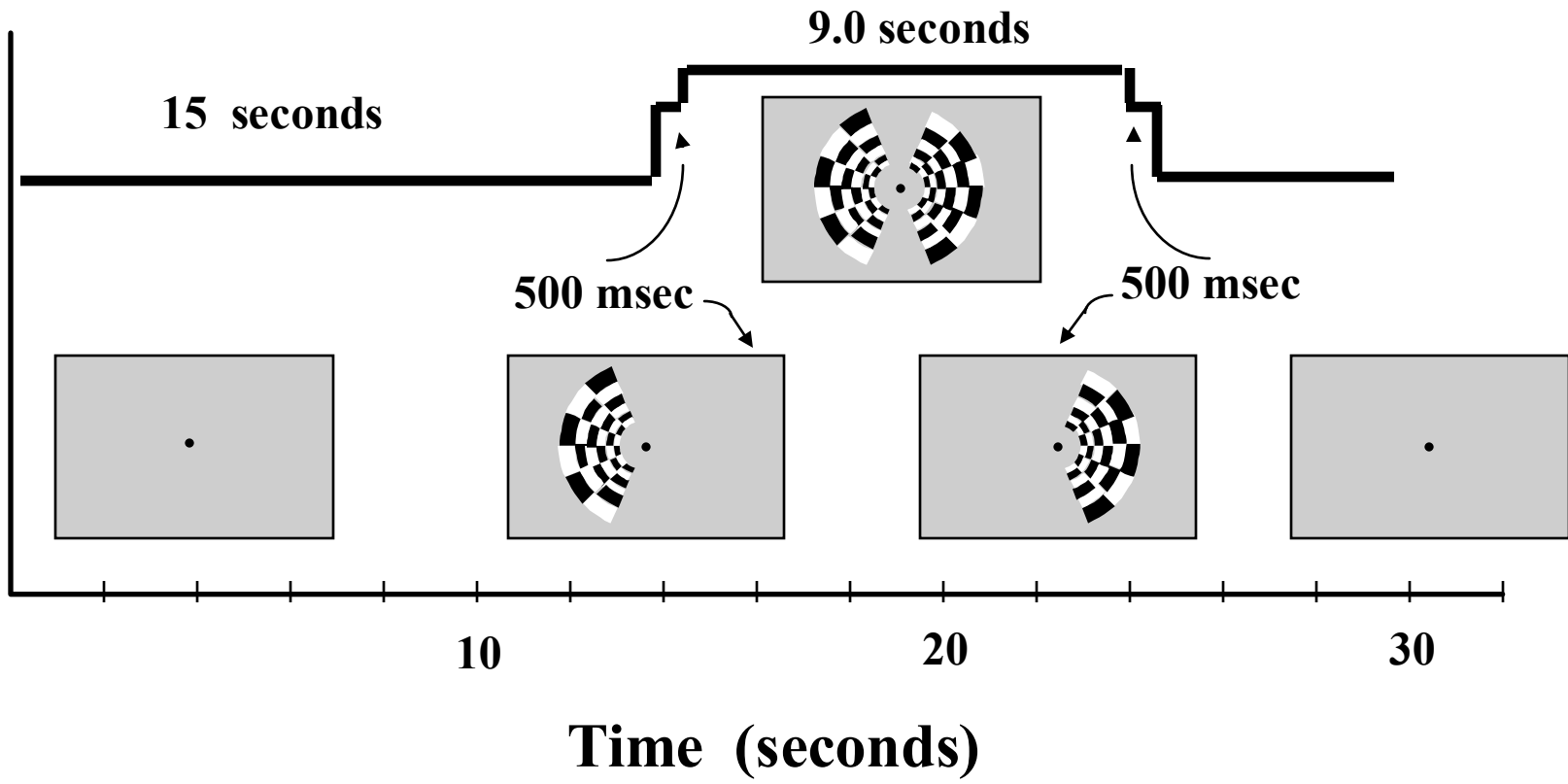


Regions of Interest Used for Hemi-Field Experiment

**Right
Hemisphere**

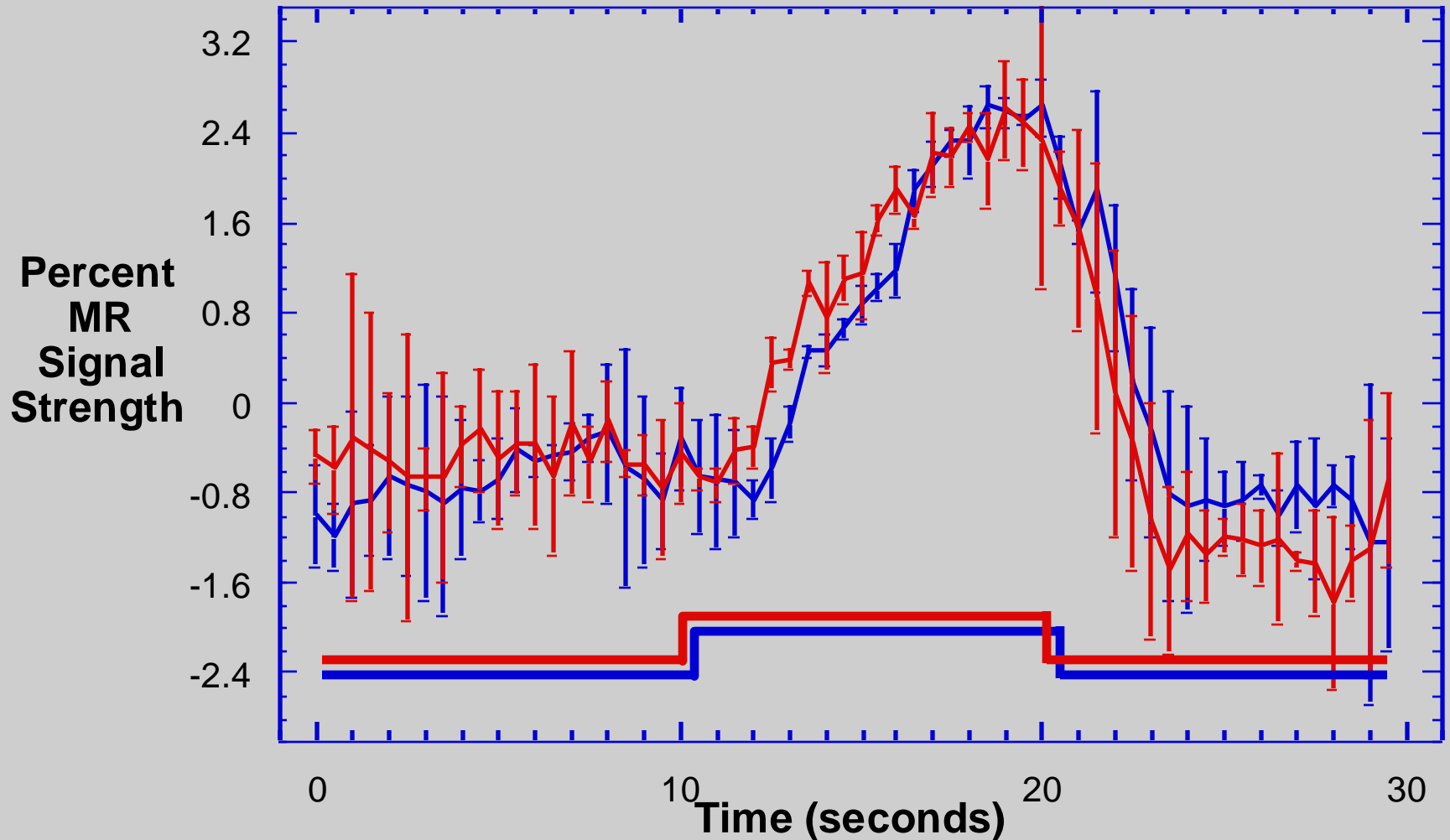


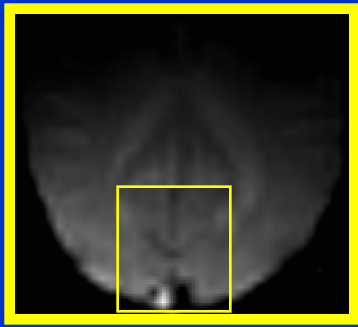
**Left
Hemisphere**




Hemi-field with 500 msec asynchrony

Average of 6 runs Standard Deviations Shown





500 ms



500 ms




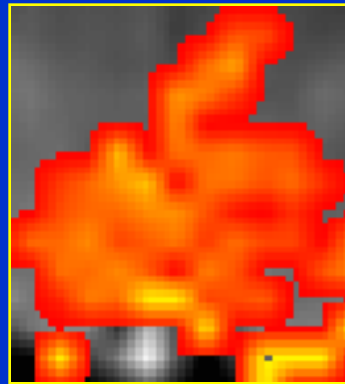
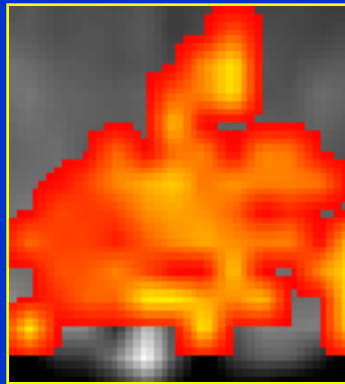

Right Hemifield

Left Hemifield

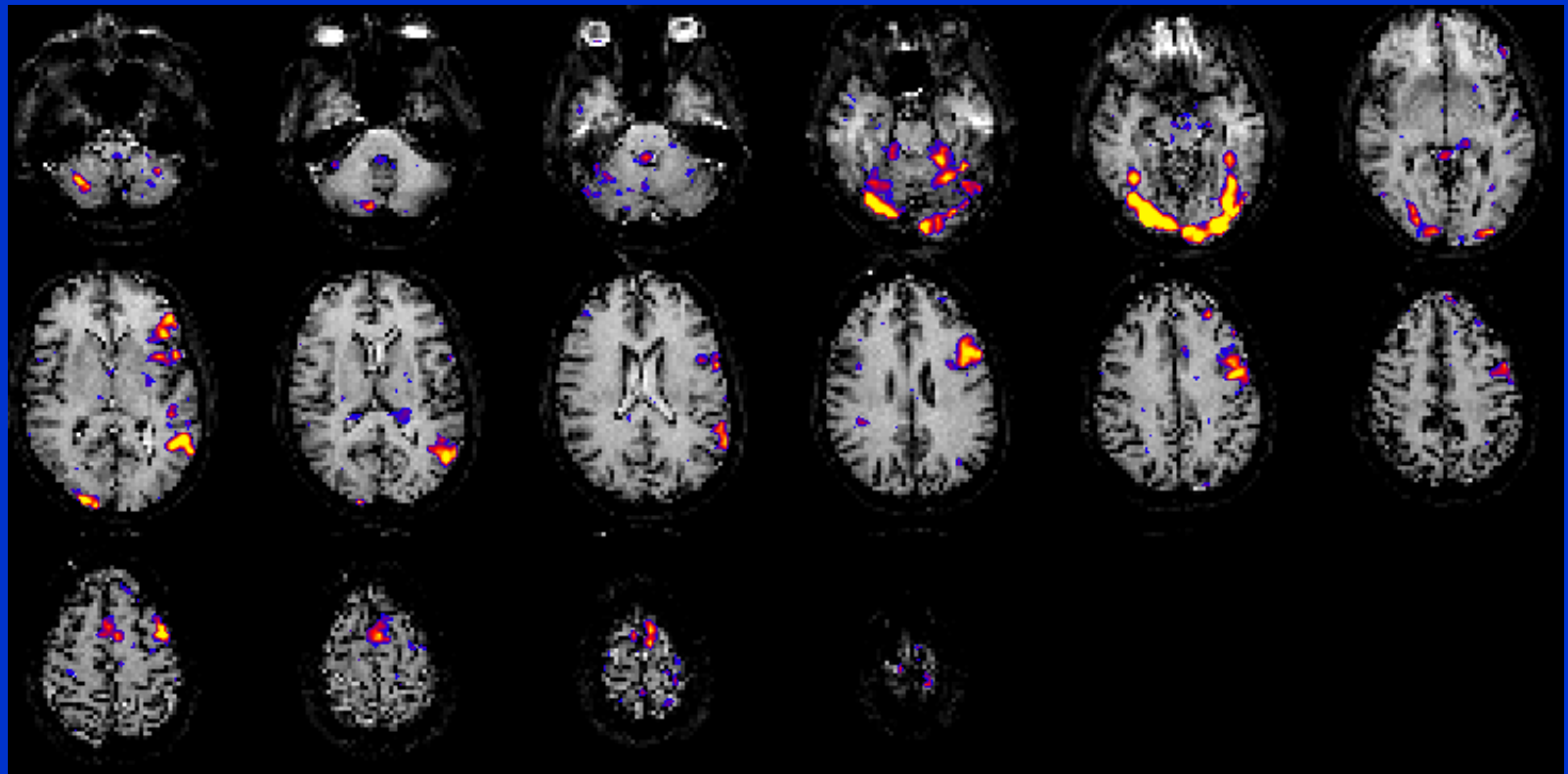
+ 2.5 s

0 s

- 2.5 s



Word stem completion



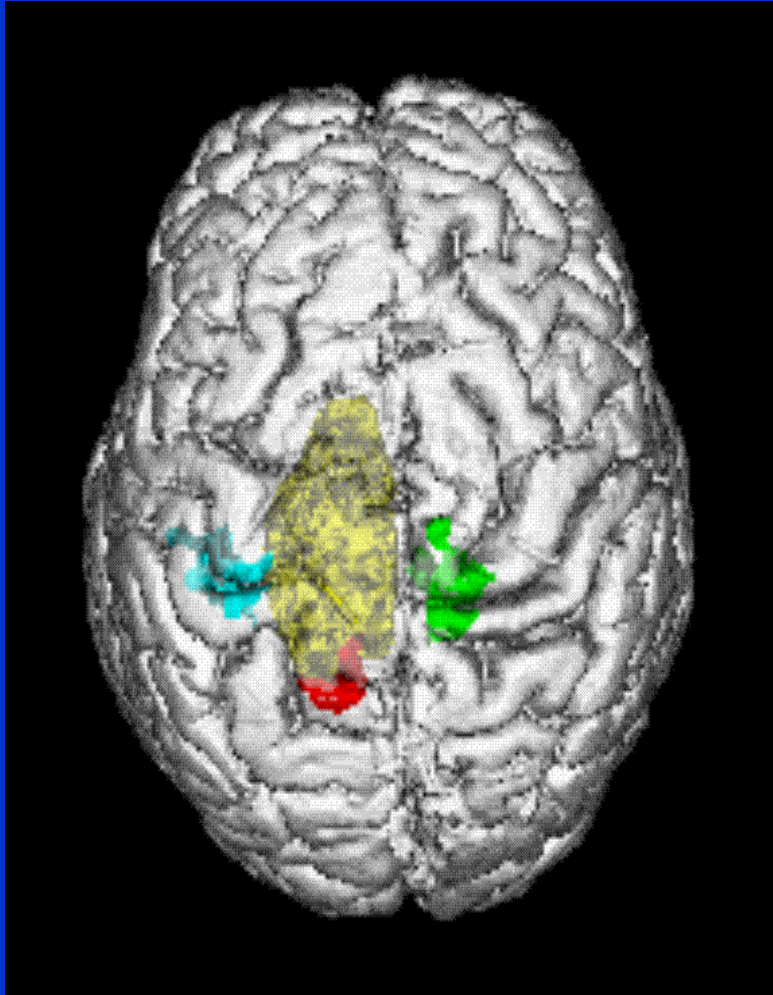
Presurgical Mapping

Left Foot

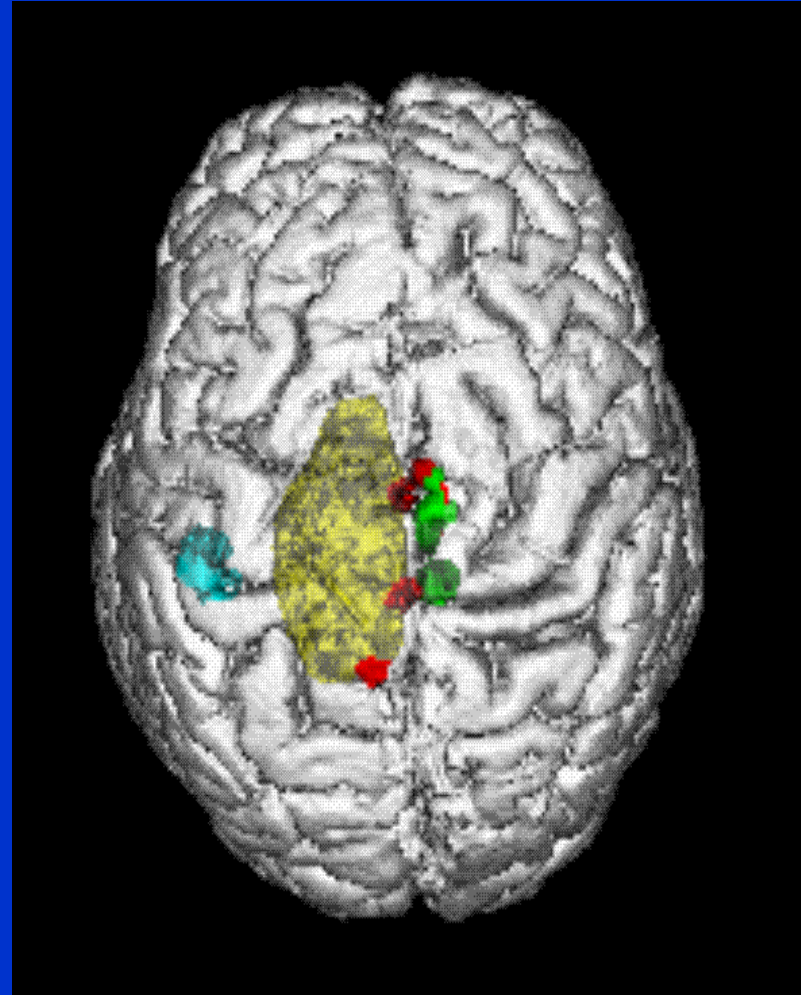
Tumor

Right Foot

Right Hand

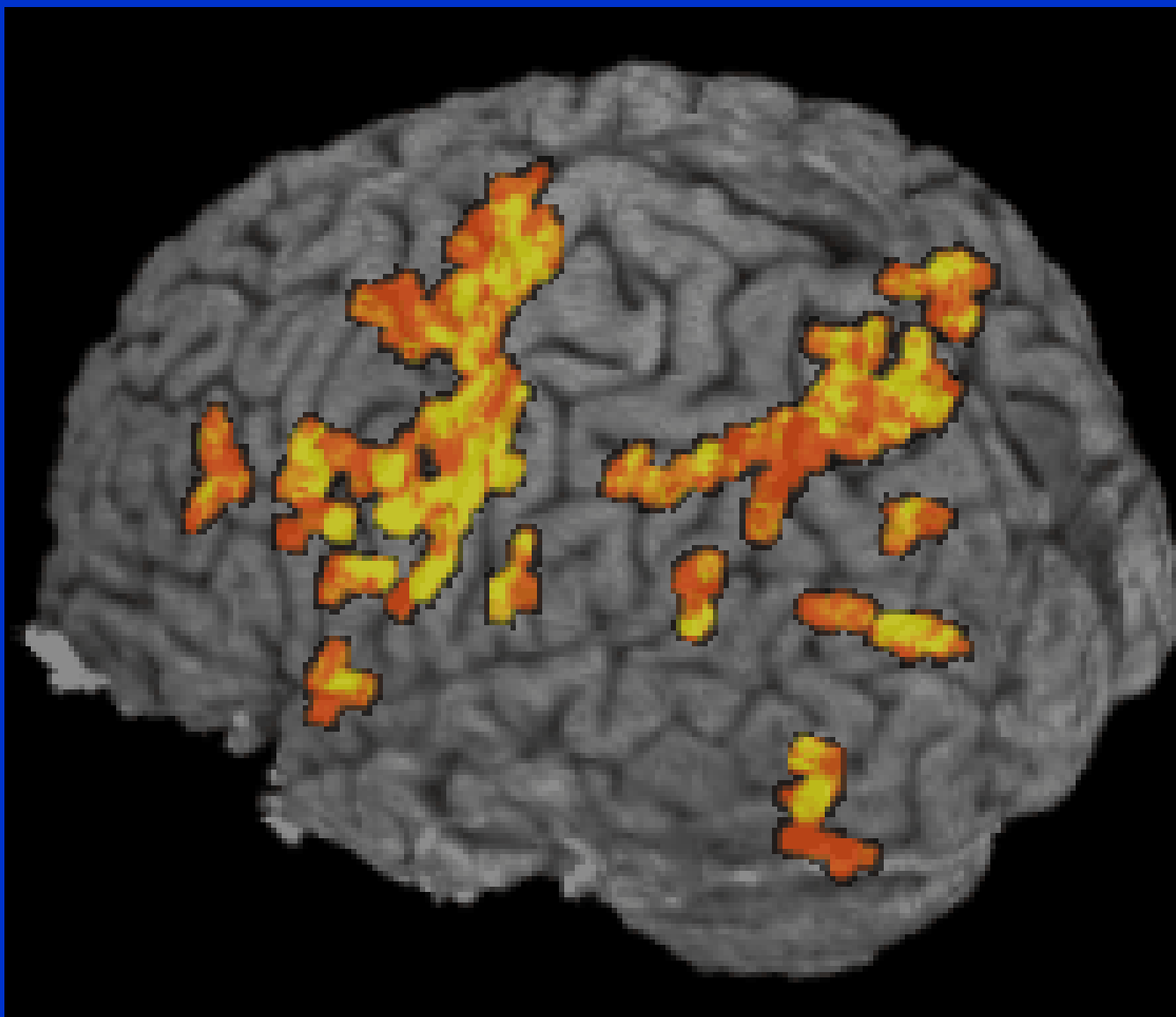


fMRI



O-15 PET

End of Acquisition



< 1 s to render

Blocked trials:

20 s on/20 s off

8 blocks

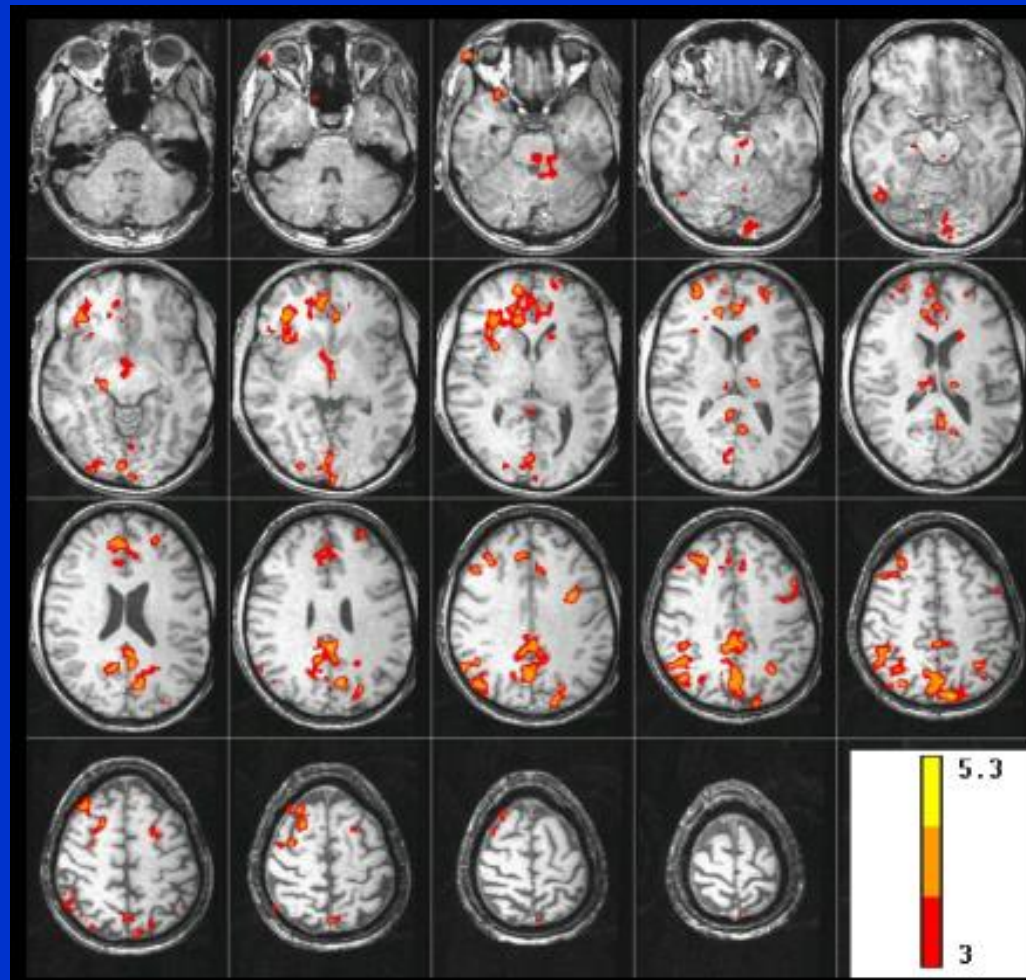
Blocks: 12345678

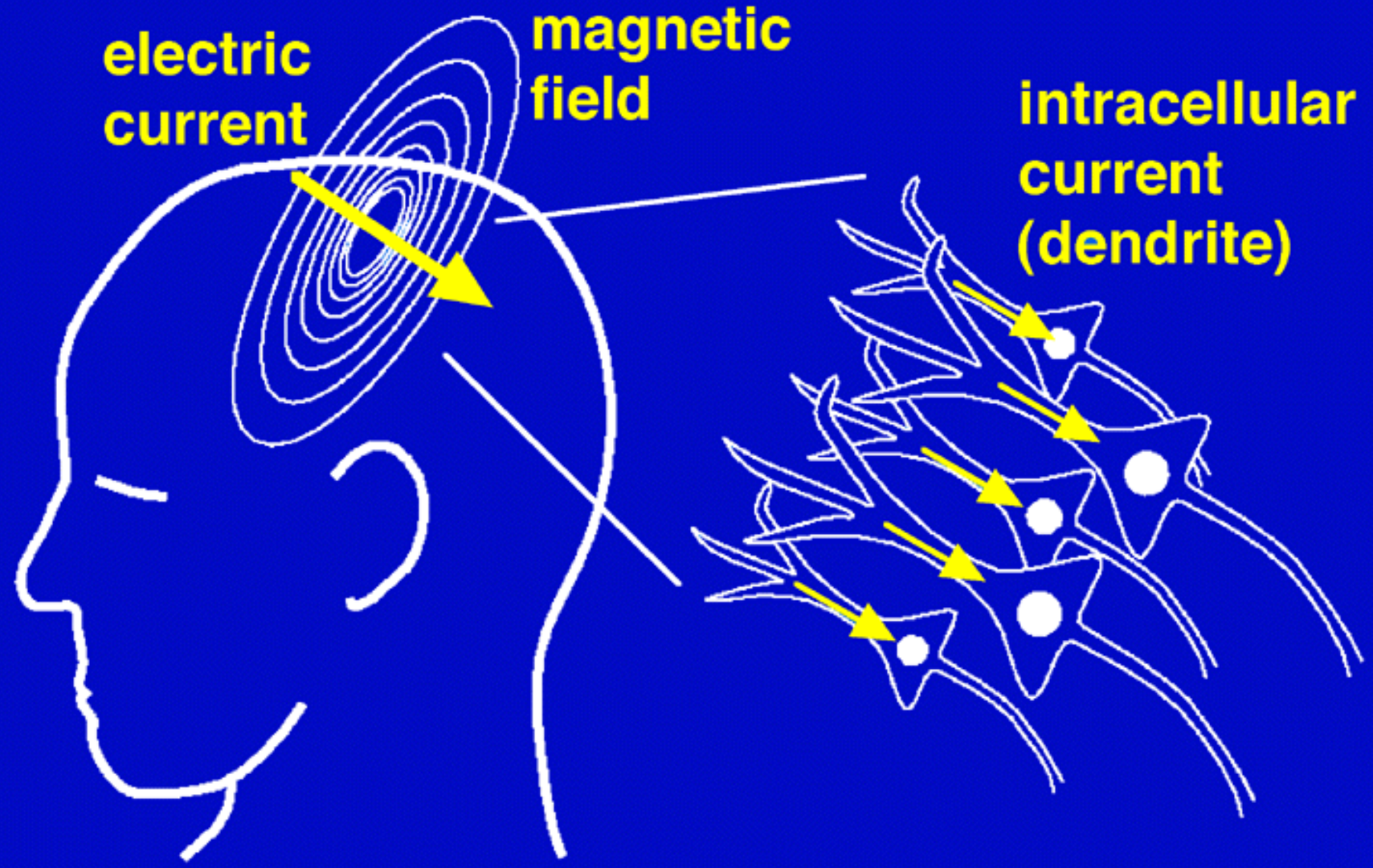
Color shows
through brain

Correlation > 0.45

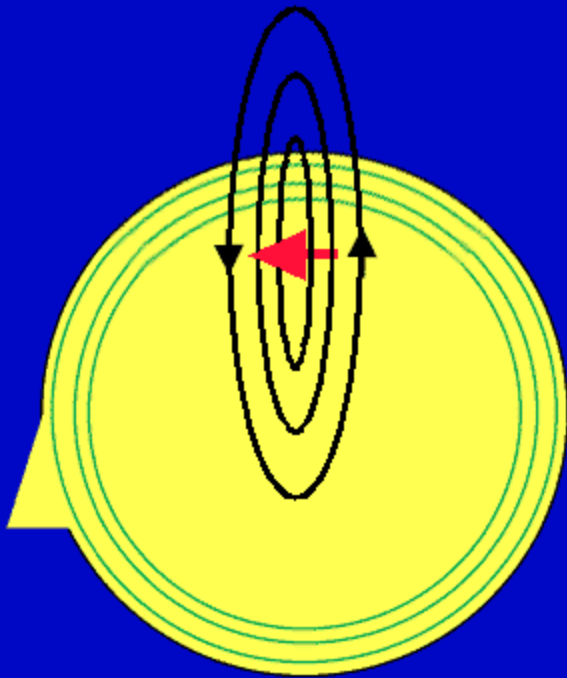
**The
End**

Activation in the brain correlated with skin conductance changes

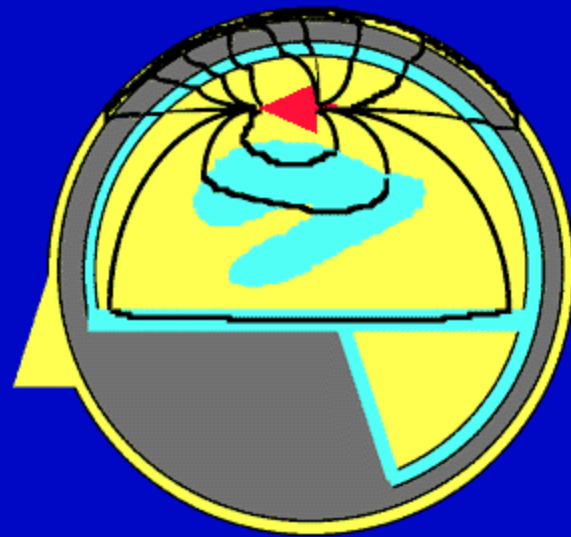


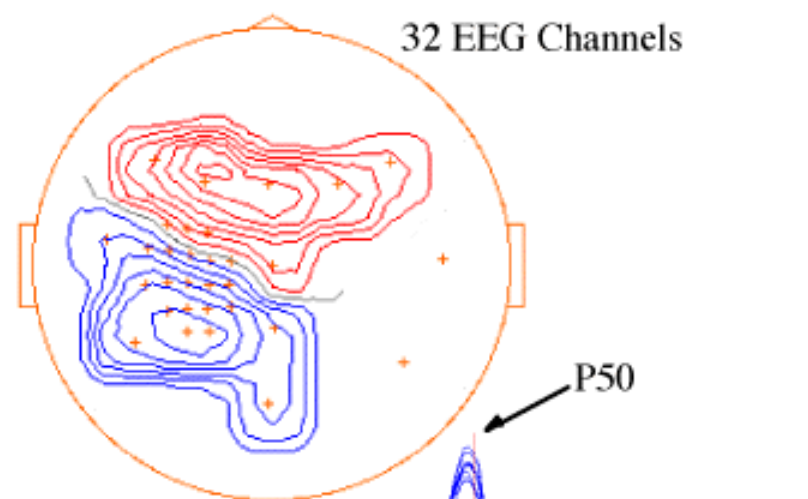
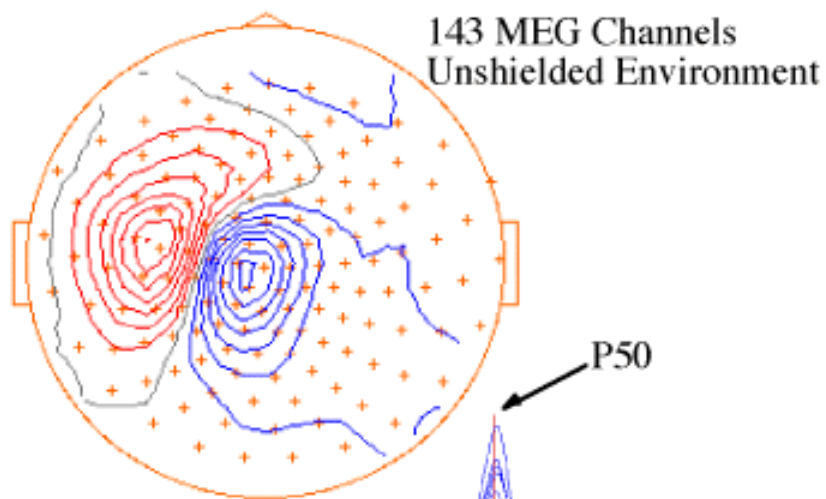


MEG



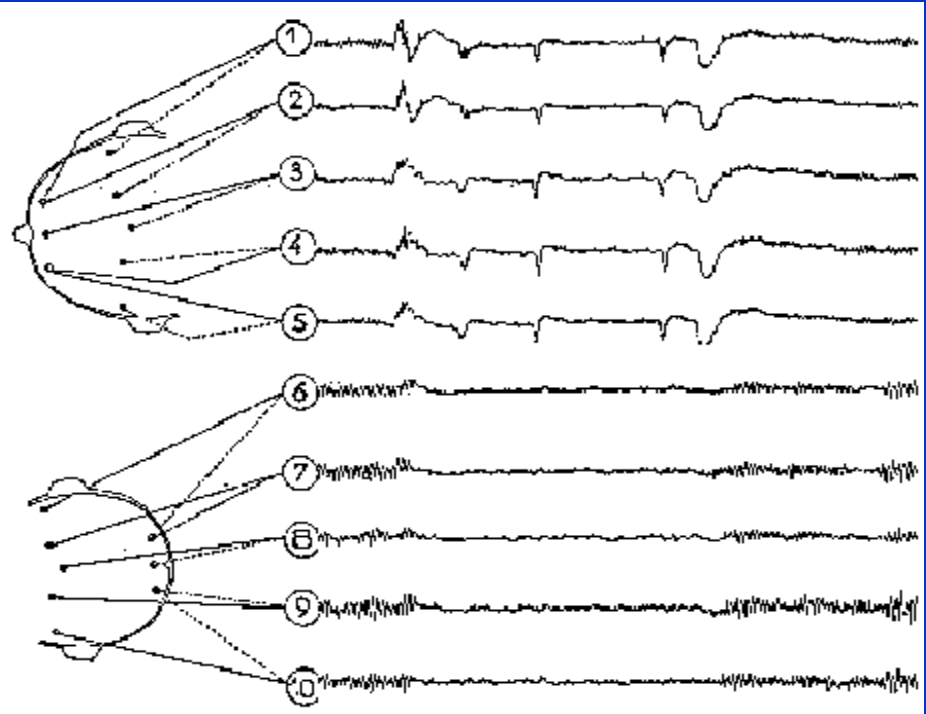
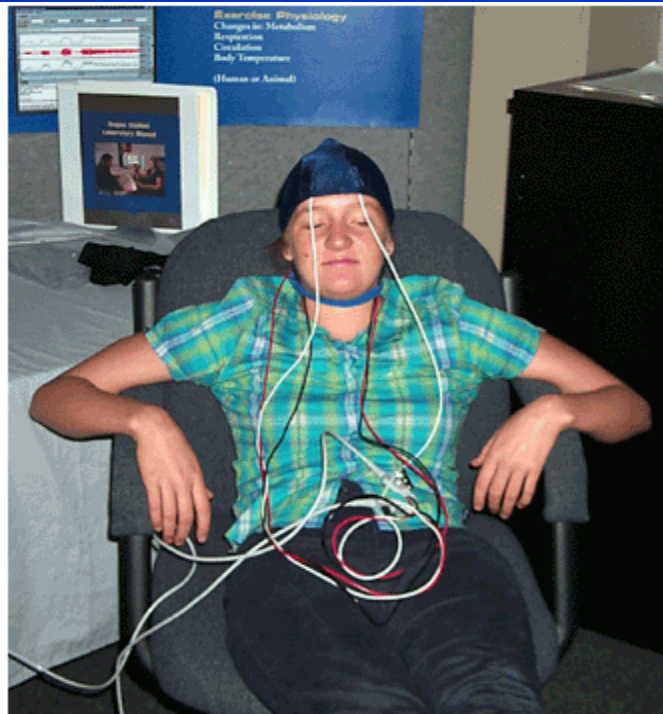EEG





Mechanical Stimulation
of Right Index Finger

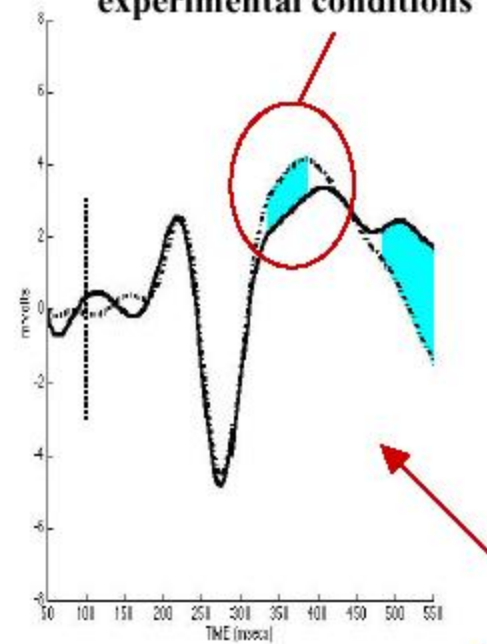
Mechanical Stimulation
of Right Index Finger



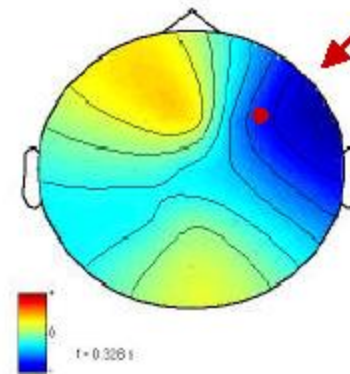
Electroencephalography (EEG) recording



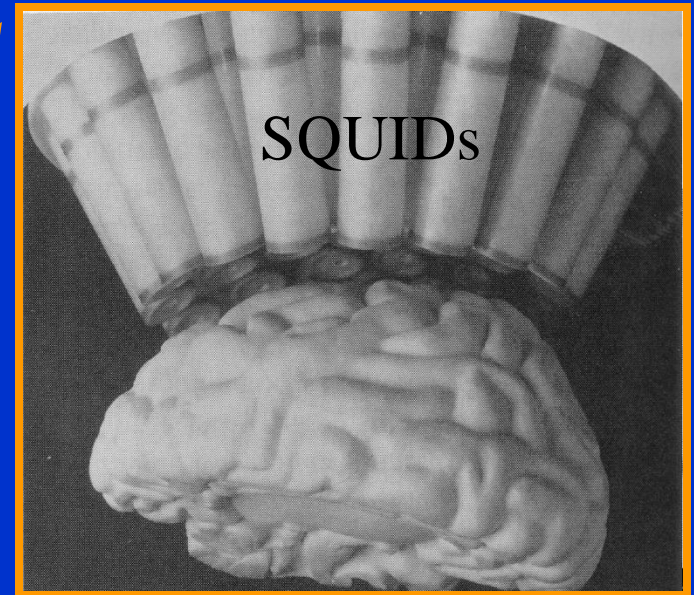
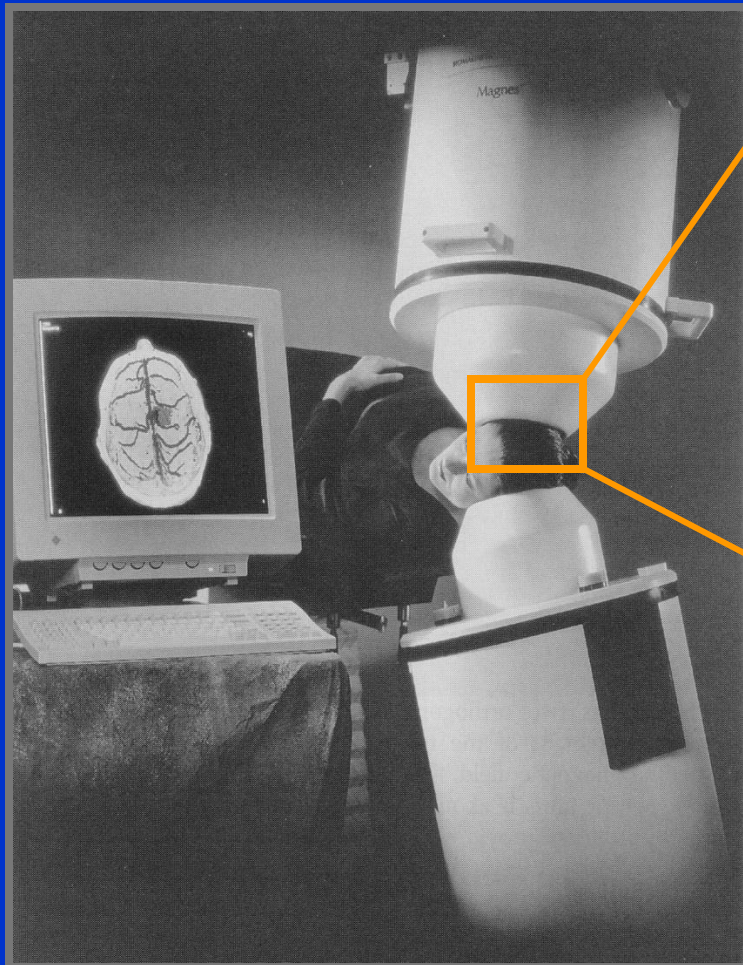
Statistical (T test) between two experimental conditions



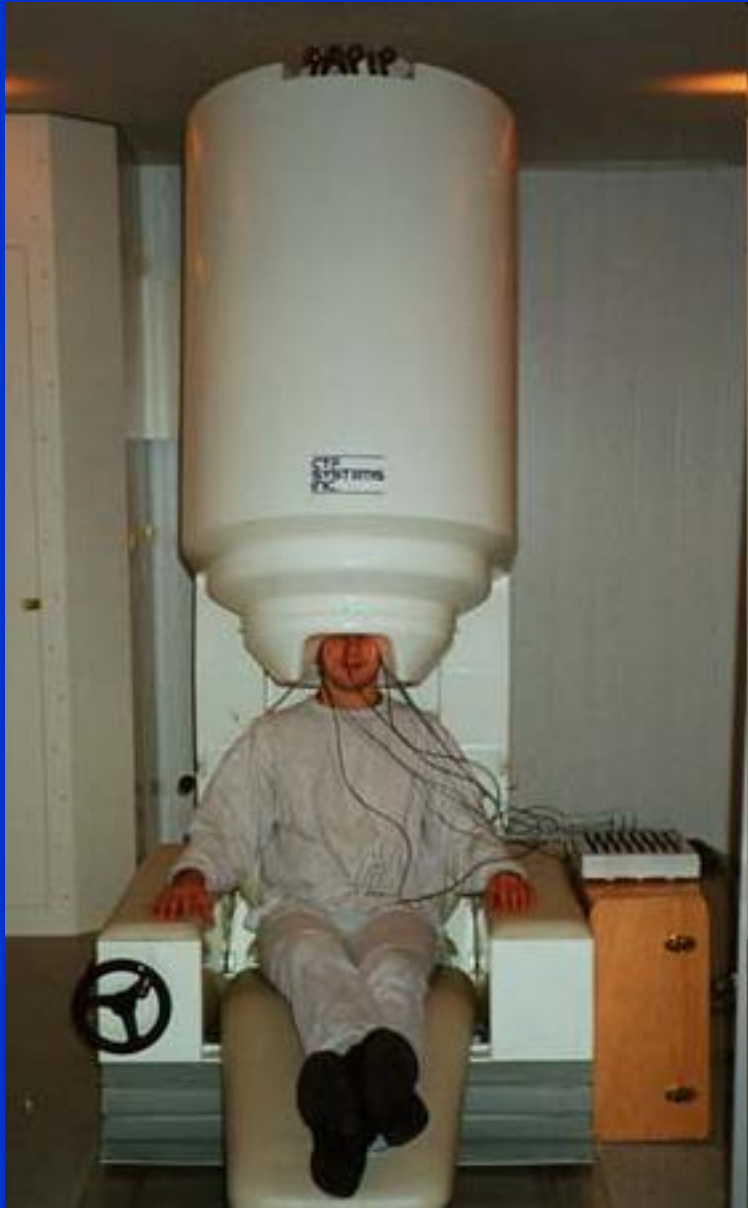F4



Magnetoencephalography (MEG)

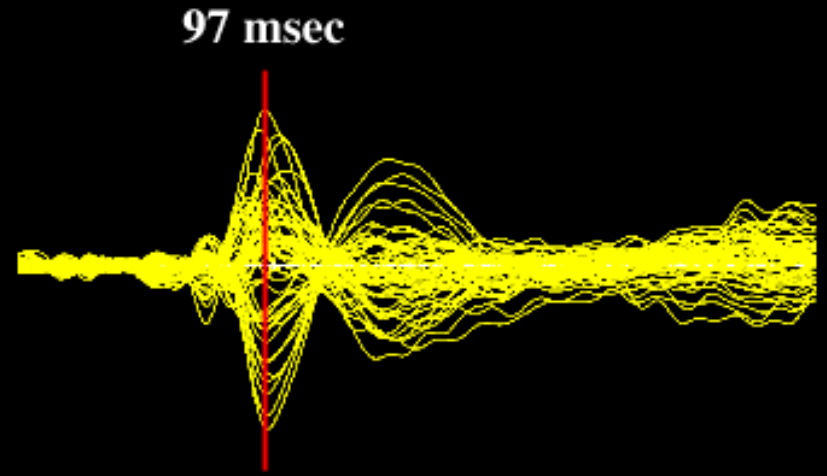
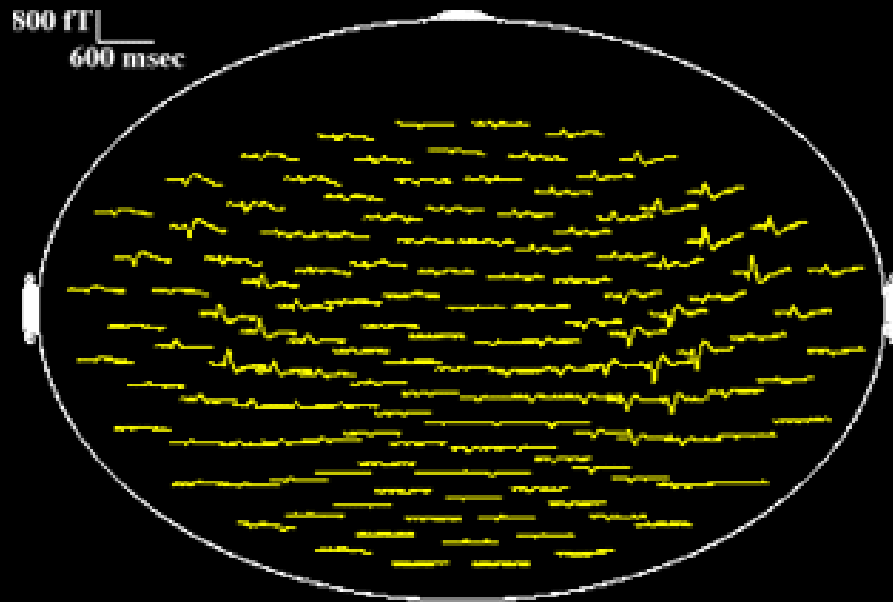


SQUID:
Superconducting Quantum
Interference Device



Combined MEG and EEG

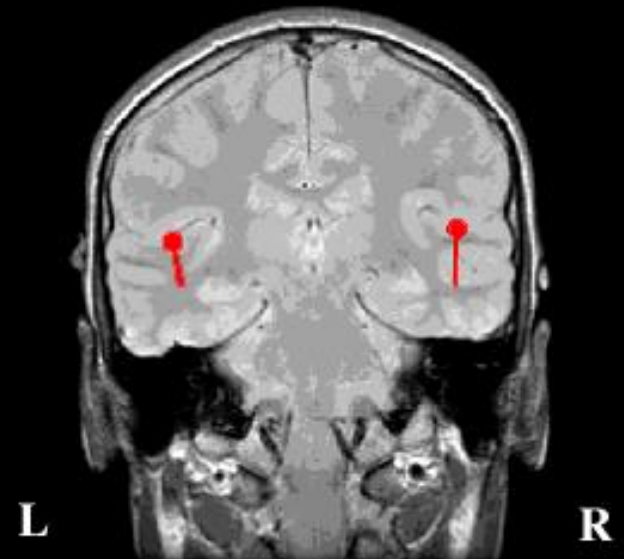
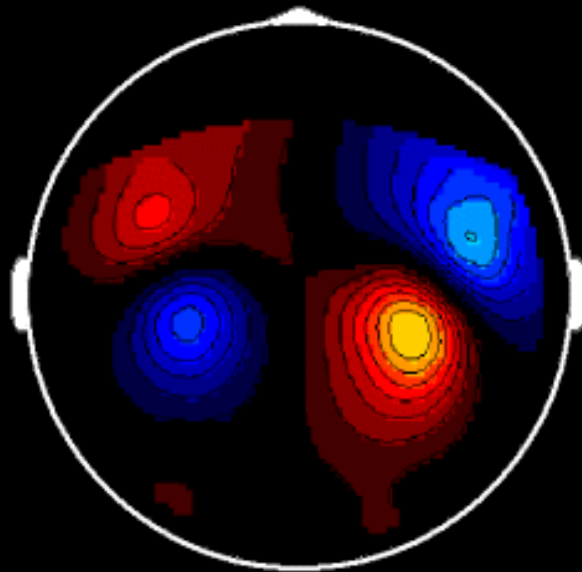
MEG Mapping



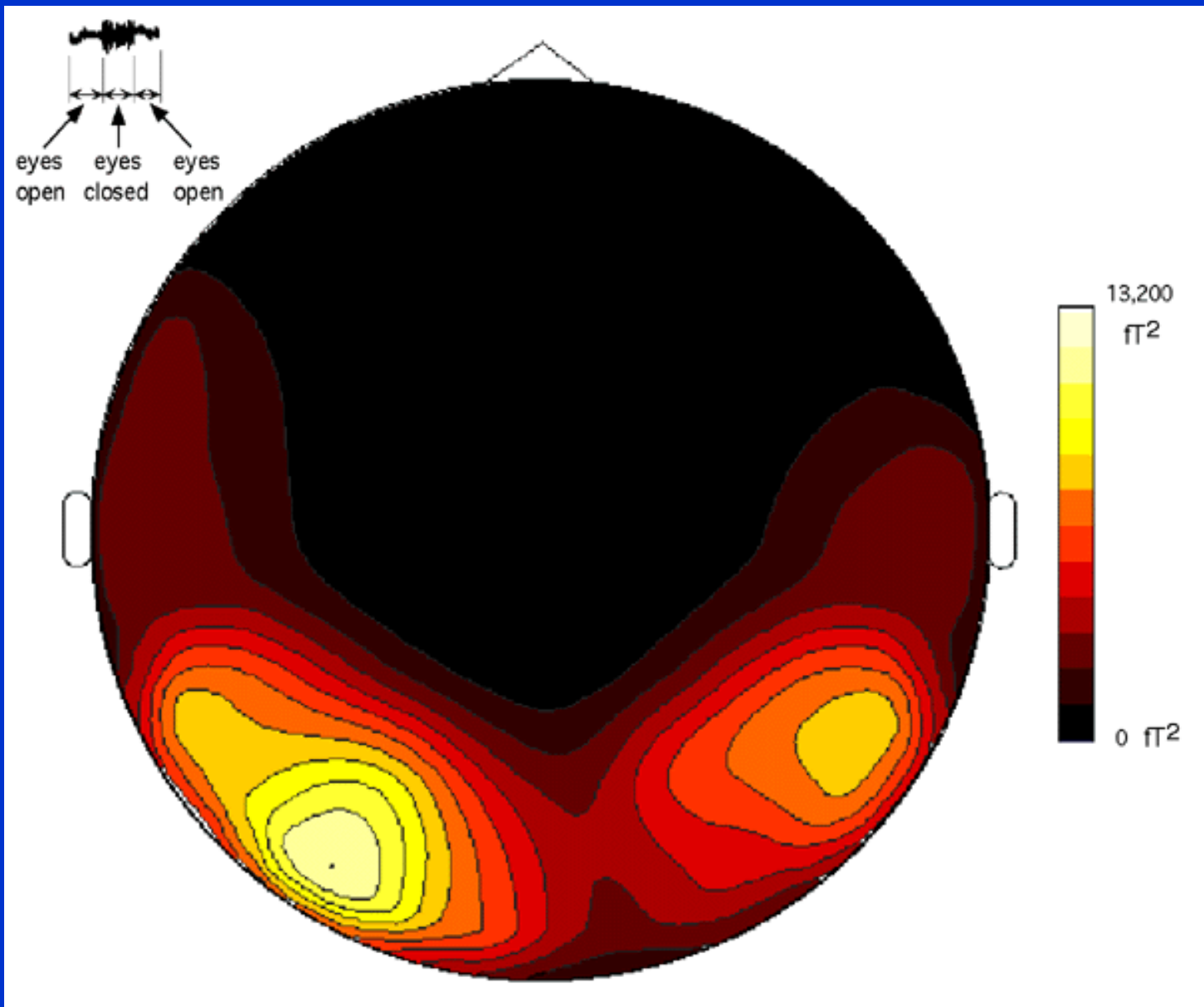
+360 fT



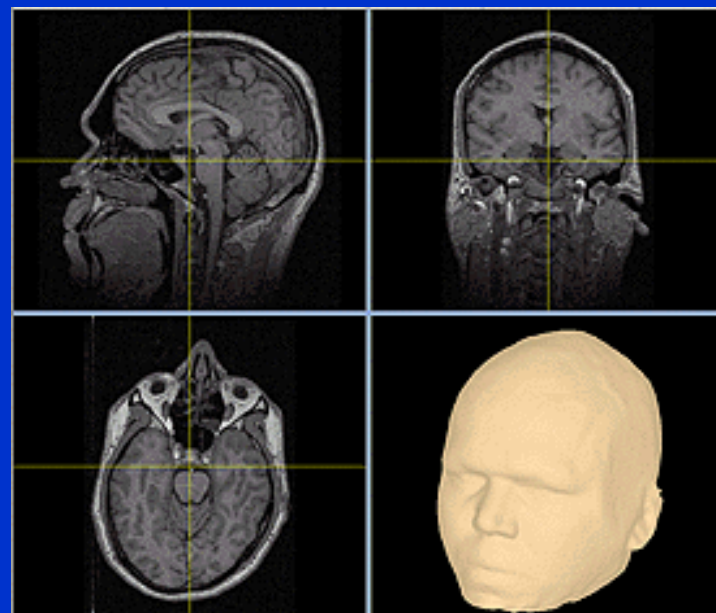
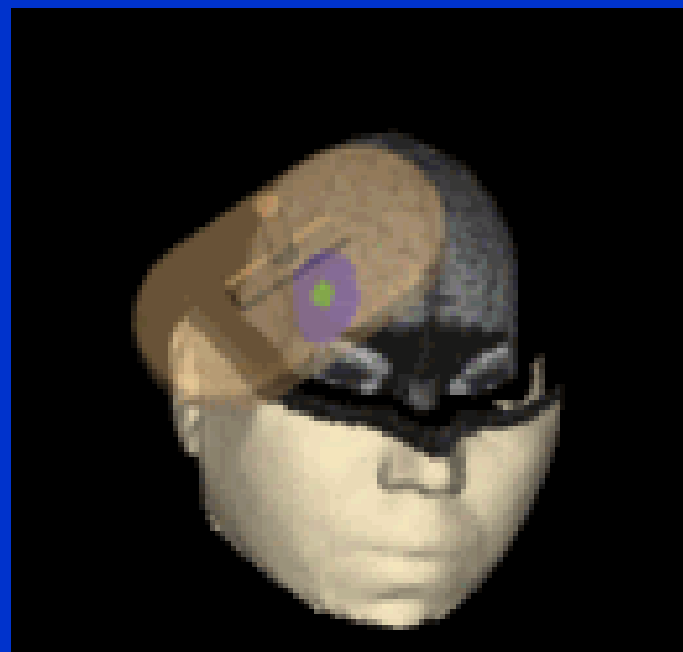
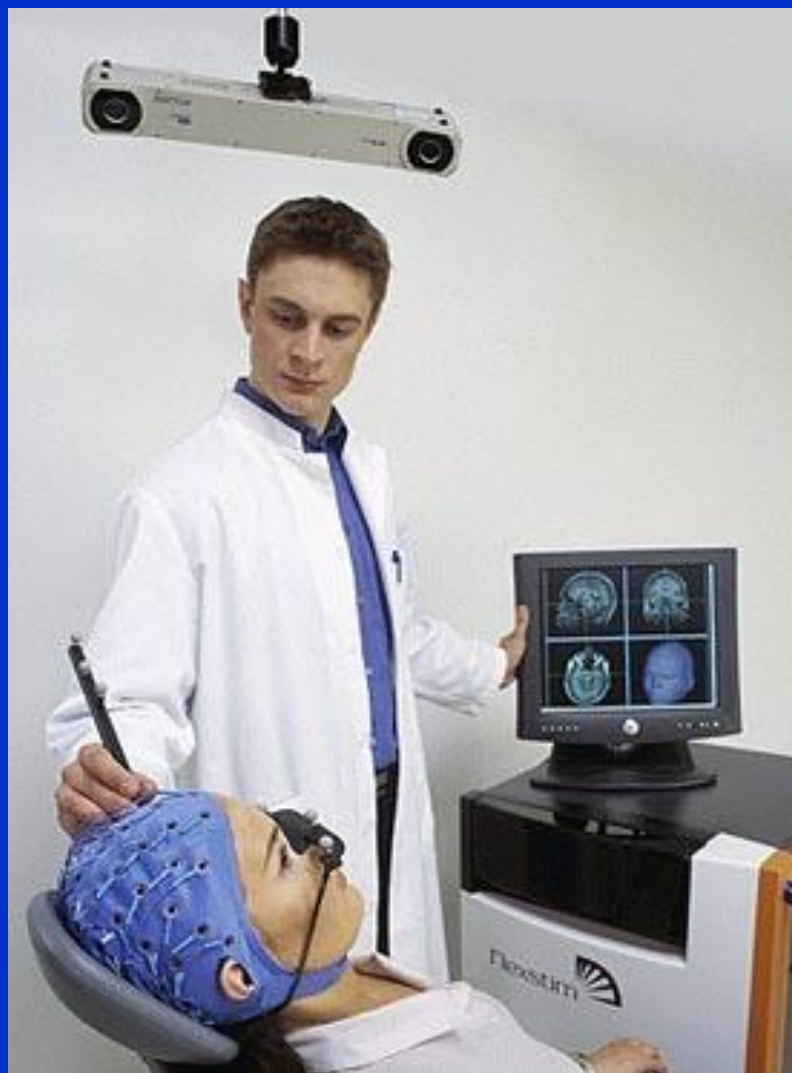-360 fT



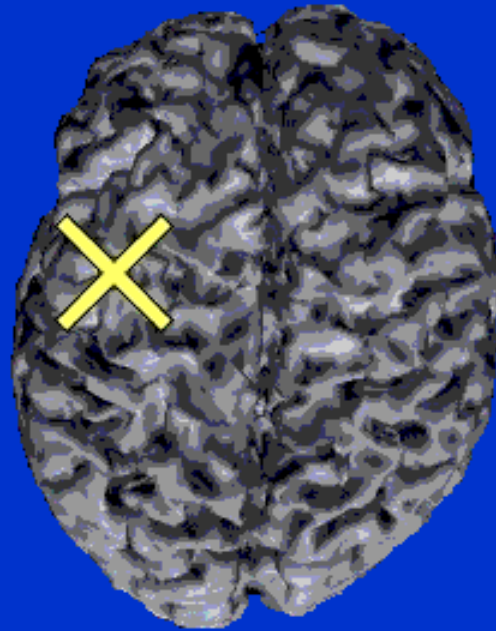
Alpha Wave Activity Mapped with MEG



Transcranial Magnetic Stimulation



Transcranial Magnetic Stimulation (TMS)



Acknowledgements

Ted Deyoe, **Medical College of Wisconsin**
Kathleen Schmainda, **Medical College of Wisconsin**
Steven Rao, **Medical College of Wisconsin**
Robert Savoy, **Massachusetts General Hospital**
Roger Tootell, **Massachusetts General Hospital**
Bradley Bookbinder, **Massachusetts General Hospital**
Randy Buckner, **Washington University, St. Louis**
Robert Innis, **National Institute of Mental Health**
Richard Coppola, **National Institute of Mental Health**
Sosumu Mori, **Johns Hopkins University**
Robert Cox, **National Institute of Mental Health**
Ziad Saad, **National Institute of Mental Health**
Eric Wong, **University of California, San Diego**
Ravi Menon, **University of Western Ontario**
Nikos Logotheddis, **Max Plank Institute, Germany**

FIM Unit & FMRI Core Facility

Director:

Peter Bandettini

Staff Scientists:

Sean Marrett

Jerzy Bodurka

Frank Ye

Wen-Ming Luh

Computer Specialist:

Adam Thomas

Post Docs:

Rasmus Birn

Hauke Heekeren

David Knight

Patrick Bellgowan

Ziad Saad

Graduate Student:

Natalia Petridou

Post-Back. IRTA Students:

Elisa Kapler

August Tuan

Dan Kelley

Visiting Fellows:

Sergio Casciaro

Marta Maieron

Guosheng Ding

Clinical Fellow:

James Patterson

Psychologist:

Julie Frost

Summer Students:

Hannah Chang

Courtney Kemps

Douglass Ruff

Carla Wettig

Kang-Xing Jin

Program Assistant:

Kay Kuhns

Scanning Technologists:

Karen Bove-Bettis

Paula Rowser

